

The Role of Ultrasonography in the Diagnosis of Degenerative Disease of the Lumbar Intervertebral Discs

Rizvan Ya Abdullaiev

Department of Ultrasound Diagnostics, Kharkiv Medical Academy of Postgraduate Education, Ukraine

Correspondence should be addressed to Rizvan Ya Abdullaiev, rizvanabdullaiev@gmail.com

Received: May 12, 2020; Accepted: May 26, 2020; Published: June 02, 2020

ABSTRACT

BACKGROUND

Degenerative changes in the intervertebral discs occupy a leading place among the causes of lower back pain. The most common diagnostic method for hernia and disc protrusion is MRI. In some patients, its use may be limited. Ultrasonography is an alternative method for diagnosing degenerative changes in discs and the causes of low back pain.

OBJECTIVE

To determine the frequency of herniated or protruded discs in patients with lumbar back pain and to correlate clinical symptoms with ultrasound findings.

MATERIAL AND METHODS

An analysis of the results of ultrasonography of 127 patients with lower back pain caused by degenerative changes in the discs in the form of hernias (86 discs) and protrusion (73 discs) was performed. In 37 patients, spinal stenosis was diagnosed, 25 of them underwent a laminectomy.

RESULTS

Lumbago was observed in 42 (33,1%) patients, sciatica - in 54 (42.5%), lumbago in combination with sciatica - in 31 (24.4%) patients, respectively. A total of 86 herniated and 73 protruded discs were defined.

Among patients with lumbago hernia was diagnosed in 14 (16.3% ± 3.9%) cases, with Sciatica in 45 (52.3% ± 5.4%) cases, with a combination of Lumbago and Sciatica - in 27 (31.4% ± 5.0%) cases, respectively. Protrusion was diagnosed in 35 (47.9% ± 5.8%), in 23 (31.5% ± 5.4%) and in 15 (20.6% ± 4.7%) cases, respectively. A hernia was significantly more frequently observed among patients with sciatica ($P < 0.001$) and protrusion among patients with lumbago ($P < 0.001$ and $P < 0.05$).

Citation: Rizvan Ya Abdullaiev, The Role of Ultrasonography in the Diagnosis of Degenerative Disease of the Lumbar Intervertebral Discs. J Clin Cases Rep 4(4): 101-109.

2582-0435/© 2021 The Authors. Published by TRIDHA Scholars.

In 13 (15.1% \pm 3.9%) the herniated discs was median, in 31 (36.0% \pm 5.2%) - paramedian and in 42 (48.9% \pm 5.4%) - foraminal types. In 37 cases was diagnosed spinal stenosis caused by the degenerative changes in the discs. 25 patients underwent laminectomy for moderate and severe spinal stenosis. In 12 (92.3% \pm 7.4%) cases spinal stenosis was caused by a median hernia, in 23 (74.2% \pm 7.9%) cases by a paramedian hernia and in 2 (4.8% \pm 3.2%) cases by a foraminal hernia. Severe spinal stenosis was significantly more frequent due to the median hernia ($P < 0.001$).

CONCLUSION

The ultrasonography can be used not only as a screening for detecting degenerative changes in the discs, but also for accurate diagnosis of hernia and protrusion. The results of ultrasonography in most cases explain the clinical symptoms of back pain. It was found that sciatica more often occurs in the presence of foraminal and paramedian hernia at the level of L5-S1, severe stenosis of the spinal canal - in patients with median hernia.

KEYWORDS

Low back pain; Lumbago and sciatica; Lumbar disc hernia and protrusion; Ultrasound diagnostics

1. INTRODUCTION

In childhood, the hydrophilicity of the intervertebral discs reaches about 85%. With age, the dehydration of the discs occurs, and already in old age the amount of water in them decreases to 70%. In some people, in the presence of a number of factors, the dehydration process occurs early and more progressively in adolescence, and this leads to changes in the shape and geometry of the discs [1]. Throughout life, cell density gradually decreases, the metabolite transport increases, and un a certain moment this process stops [2]. After completion of further skeletal growth, the density of the pulposus nucleus is usually 25% of the density of the fibrous ring. Biochemical changes in the pulposus nucleus lead to a decrease in hydrostatic pressure in it and also its volume. In the future, it is displaced and protruded towards the fibrous ring [3]. Slight protrusion of the disc, due to age, is not pathological and is not accompanied by back pain. In this case, MRI can already detect a slight decrease in the hydrophilicity of the disk [4].

If normal discs lose height $< 1\%$ per year, then degeneration discs, about 3% per year [5]. The height of the fibrous ring largely determines the separation of the surrounding nerve plexuses, therefore, an increase in the

area of the disk due to a decrease in its height causes a strong compression load on the apophysial joints [6]. In addition, loss of disc height weakens the intervertebral ligaments, which leads to segmental instability of the vertebral bodies [7].

In front, the height of the lower lumbar intervertebral discs is higher than in the back, and behind the fibrous ring is thinner than in front. This characteristic can help the discs dissipate energy from sudden compression overload during extension and, at the same time, makes them more vulnerable to injuries when bending forward. Degeneration caused by damage to the locking plate often develops at a younger age, since the main structural defects of the locking plate may be congenital in origin. Degeneration involving the fibrous ring in the process tends to increase throughout life, since it depends more on the accumulation of repeated injuries than on birth defects, and also because age-related biochemical changes make the fibrous ring more vulnerable to mechanical stress. The clinical consequences of degeneration caused by damage to the endplate can be relatively less serious, since the underlying damage to the bone endplate and vertebral body can heal. On the

contrary, the relatively low healing potential of the fibrous ring can lead to repeated injuries, an enhanced inflammatory reaction and more severe pain from the nerve root innervating the fibrous ring [8].

On the one hand, the acceleration of biochemical and functional changes in aging on some discs, especially in the lower lumbar spine, on the other hand, mechanical damage to the disc contributes to the development of degenerative disease. According to the results of MRI, there is a correlation between the decrease in T2 signals and the degree of dehydration of the pulpous nucleus of the intervertebral discs [9].

Throughout life, approximately 60% - 90% of the population may experience back pain. The spinal segment L5-S1 is the most common source of lower back pain. Due to the forces acting on this segment, as well as the range of motion it provides, it is prone to injury or degeneration [10]. The term "lower back pain" refers to "pain limited to the area between the lower edges of the 12th rib and the gluteal folds". It is the most common type of back pain [11].

A large number of previous studies show a relationship between degenerative changes in the intervertebral discs and back pain or sciatica. It should be noted that back pain most often occurs when there is a crack or rupture of the fibrous ring, structural changes in the endplates of the vertebral body and prolapse of the fibrous ring, leading to a significant narrowing of the spinal canal [12,13].

Severe back pain is closely related to radial cracks that reach the periphery of the disc. The innervation of the fibrous ring is usually limited to a depth of 3 mm at its periphery, although nerves can grow further along radial fissures [14]. Intense pain arising from the periphery of the fibrous ring was demonstrated in studies using provocation and blocking, and can be attributed to sensitization of nerves in destroyed and inflamed tissue,

enhanced by diffusion of chemicals from the internally displaced pulpous nucleus [15].

Often, the causes of back pain are multifactorial. One of the pathogenetic mechanisms of back pain can be an inflammation of the epidural space due to hypothermia, uncomfortable forced position of the body, unbalanced weight lifting. Low back pain can manifest as lumbago or sciatica. In such cases, it is very important to determine the intensity and nature of the pain, the area of their spread.

Given that disc herniation is the most common cause of radiculopathy, its diagnosis is important. Many clinical studies have been devoted to the study of this issue. Each of them individually does not explain all the questions that have arisen and only partially cover some aspects of lumbar radiculopathy [16,17].

Accurate diagnosis of radiculopathy requires a comparison of clinical symptoms and the results of MRI or CT, allowing visualization of protrusion or hernia of the disk, to determine stenosis of the spinal canal, the presence of an inflammatory process in the epidural space [18,19].

An alternative method of imaging the intervertebral discs of the cervical and lumbar spine is ultrasonography. The American Institute of Ultrasound in Medicine (AIUM) and Ultrasound Practice Accreditation Council (UPAC) has developed standards for the accreditation of ultrasound practices [20,21].

From the clinical point of view, the solution to the problem of vertebrogenic pain involves the definition of the source of pain, the establishment of its mechanisms and paths for its elimination. The lumbar plexus block can be used as the only method or in combination with the sciatic nerve block for pain relief in back pain with sciatica. The lumbar plexus is located in an intramuscular fascial plane within the posterior one-third of the psoas

muscle and is very closely related to the lumbar transverse processes [22].

2. OBJECTIVE

To determine the frequency of herniated or protruded discs in patients with lumbar back pain and to correlate clinical symptoms with ultrasound findings.

3. MATERIAL AND METHODS

The study included 127 patients with lower back pain of unilateral localization. Back pain was divided into the following types: lumbago, sciatica, lumbago in combination with sciatica. Among all patients, only hernia was diagnosed in 53 cases, only protrusion - in 48 cases, hernia in combination with protrusion at 2 lumbar levels - in 19 persons (21 hernia and 16 protrusion) and at 3 lumbar levels - in 7 persons (12 hernia and 9 protrusion) was diagnosed (total 98 hernia and 86 protrusion), respectively.

In 54 cases, these changes in the discs contributed to the development of spinal stenosis. 28 patients underwent laminectomy in 37 disks for spinal canal stenosis. The age of patients ranged from 27 years to 62 years, of which 73 men, and 54 women.

All patients underwent X-ray, MRI and ultrasonography. Ultrasonography (USG) was conducted on a Philips HD 11 XE device using a convection transducer in the frequency range 2 MHz - 5 MHz; MRI - General Electric, Signa HDI, 1.5T.

Differences in the proportion correctly localized lesions were tested using the chisquare statistic. P-values <0.05 were considered statistically significant.

4. RESULTS

Back pain was divided into the following types: lumbago, sciatica, lumbago in combination with sciatica. Lumbago was observed in 42 (33.1%) patients, sciatica - in 54 (42.5%), lumbago in combination with sciatica - in 31

(24.4%) patients, respectively. Among the examined patients, at one lumbar level, only a herniated discs in 53 cases and only protruded discs in 47 cases was defined. In 19 patients, degenerative changes were diagnosed at two lumbar levels - 21 herniated and 17 protruded discs. In 7 cases, degenerative changes were diagnosed at three lumbar levels - 12 herniated and 9 protruded discs. A total of 86 herniated and 73 protruded discs were defined, respectively (Table 1).

The type of degenerative changes in discs	Patients with clinical symptoms of lumbar back pain (n = 127)		
	Lumbago (L) n = 42	Sciatica (S) n = 54	L + S n = 31
	1	2	3
Hernia (n = 86 discs)	14 (16.3% ± 3.9%)	45 (52.3% ± 5.4%) P2-1 <0.001 P2-3 <0.01	27 (31.4% ± 5.0%) P3-1 <0.05
Protrusion (n = 73 discs)	35 (47.9% ± 5.8%) P3-1 <0.001 P3-2 <0.05	23 (31.5% ± 5.4%)	15 (20.6% ± 4.7%)
Total (n = 159 discs)	49 (30.8% ± 3.7%)	68 (42.8% ± 3.9%) P2-1 <0.05 P2-3 <0.01	42 (26.4% ± 3.5%)
Disc lesion index	1.17 (49/42)	1.26 (68/54)	1.35 (42/31)

Table 1: The relationship between clinical symptoms of lumbar back pain and the type of degenerative changes in the lumbar discs.

Among patients with lumbago hernia was diagnosed in 14 (16.3% ± 3.9%) cases, with Sciatica in 45 (52.3% ± 5.4%) cases, with a combination of Lumbago and Sciatica - in 27 (31.4% ± 5.0%) cases, respectively. Protrusion was diagnosed in 35 (47.9% ± 5.8%), in 23 (31.5% ± 5.4%) and in 15 (20.6% ± 4.7%) cases, respectively. As can be seen from table 1, a hernia was significantly more frequently observed among patients with sciatica (P<0.001 and P<0.01), and protrusion among patients with lumbago (P<0.001 and P<0.05).

Among patients with lumbago, the total number of degeneratively altered discs was 49 (30.8% ± 3.7%), with sciatica - 68 (42.8% ± 3.9%) and with a combination of lumbago and sciatica - 42 (26.4% ± 3.5%). As can be seen from the table 1 the total number of discs with hernia and protrusion among patients with sciatica was significantly greater than in the other groups (P<0.05 and P <0.01). We compiled a lesion index of discs for various

clinical symptoms. For this, the total number of discs with hernia and protrusion was divided by the number of patients with one or another clinical symptoms. For patients with lumbago, the index was 1.17, for sciatica - 1.26, and with a combination of lumbago and sciatica - 1.35.

Table 2 presents the results of a study on the relationship between clinical symptoms, the nature of degenerative changes in the discs in the form of a hernia or protrusion. As can be seen from the table, among patients with lumbago, herniated disc of median localization was observed in 11 (22.4% ± 5.9%), protrusion - in 24 (49.0% ± 7.1%) cases (P<0.01); hernia of paramedian localization was noted in 2 (4.1% ± 2.8%), protrusion - in 12 (22.4% ± 5.9%) cases (P<0.01). In these patients, a hernia and protrusion of foraminal localization was not observed.

Clinical symptoms of lower back pain and quantity of degeneratively affected discs	Hernia (n = 86 discs)			Protrusion (n = 73 discs)		
	1	2	3	1	2	3
	Median	Paramedian	Foraminal	Median	Paramedian	Foraminal
	13	31	42	28	36	9
Lumbago 49 discs	11 (22.4% ± 5.9%)	2 (4.1% ± 2.8%)	-	24 (49.0% ± 7.1%) P1-1<0.01	12 (24.5% ± 6.1%) P2-2<0.01	-
Sciatica 68 discs	-	23 (33.8% ± 5.7%) P2-2<0.01	29 (42.7% ± 6.0%) P3-3<0.001	2 (2.9% ± 2.0%)	10 (14.7% ± 4.3%)	4 (5.9% ± 2.9%)
Lumbago +Sciatica 42 discs	2 (14.3% ± 5.4%)	6 (31.0% ± 7.1%) P3-3<0.05	13	2 (33.3% ± 7.3%) P2-2<0.05	14	5 (11.9% ± 5.0%)

Table 2: Localization level of affected lumbar discs and clinical symptoms.

Among patients with sciatica, herniated disc of paramedian localization was observed in 23 (33.8% ± 5.7%), protrusion - in 10 (14.7% ± 4.3%) cases (P <0.01); hernia of paramedian localization was noted in 2 (4.1% ± 2.8%), protrusion - in 12 (22.4% ± 5.9%) cases (P<0.01); hernia of foraminal localization was registered in 29 (42.7% ± 6.0%), protrusion - in 4 (5.9% ± 2.9%) cases, respectively (P<0,001). In these patients, a hernia

of median localization was not observed, protrusion was diagnosed in 2 cases.

In a patients with combination of lumbago and sciatica, herniated and protruded disc of median localization was observed in 2 cases, paramedian localization - in 6 (14.3% ± 5.4%) and 14 (33.3% ± 7.3%) cases (P<0.05); foraminal localization - in 13 (31.0% ± 7.1%) and 14 (11.9% ± 5.0%) cases, respectively (P<0.05).

The level and location of lumbar disc hernia are presented in table 3. Disc hernia was detected at the level of L3-L4, L4-L5, L5-S1. The disc location was defined as median, paramedian and foraminal. In 13 (15.1% ± 3.9%) the herniated discs was median, in 31 (36.0% ± 5.2%) - paramedian and in 42 (48.9% ± 5.4%) - foraminal types.

The median hernia in 7 (8.1% ± 2.9%) cases was localized at level of L3-L4, in 5 (5.8% ± 2.5%) - L4-L5 and in 1 (1.2% ± 1.2%) - L5-S1; the paramedian hernia - in 5 (5.8% ± 2.5%), in 14 (16.3% ± 4.0%) and in 12 (14.0% ± 3.7%) discs; the foraminal - in 4 (4.7% ± 2.3%), in 9 (10.5% ± 3.3%) and in 29 (33.7% ± 5.4%) discs respectively.

The level of lumbar discs	Hernia (n = 86 discs)		
	Median	Paramedian	Foraminal
	1	2	3
	13 (15.1% ± 3.9%)	31 (36.0% ± 5.2%) P2-1 <0.01	42 (48.9% ± 5.4%) P3-1 <0.001
L3-L4 16 (18.6% ± 4.2%)	7 (8.1% ± 2.9%)	5 (5.8% ± 2.5%)	4 (4.7% ± 2.3%)
L4-L5 28 (32.5% ± 5.1%)	5 (5.8% ± 2.5%)	14 (16,3±4,0%)	9 (10,5±3,3%)
L5-S1 42 (48.9% ± 5.4%)	1 (1.2% ± 1.2%)	12 (14.0% ± 3.7%)	29 (33.7% ± 5.4%) P3-1 <0,001 P3-2 <0,01

Table 3: The level and location of lumbar discs hernia.

The level and location of lumbar disc protrusion are presented in table 4. In 28 (38.4% ± 3.9%) discs the protrusion was median, in 36 (49.3% ± 5.9%) - paramedian and in 9 (12.3% ± 3.8%) - foraminal types.

The median protrusion in 8 (11.0% ± 3.7%) cases was localized at the level of L3-L4, in 11 (15.1% ± 4.2%) cases - at the level of L4-L5 and in 9 (12.3% ± 3.8%) cases - at the level of L5-S1; the paramedian protrusion - in 9 (12.3% ± 3.8%), in 13 (17.8% ± 4.5%), and in 14 (19.2% ± 4.6%) cases; the foraminal - in 4 (5.5% ± 2.7%), in 3 (4.1% ± 2.3%) and in 2 (2.7% ± 1.9%) cases, respectively (Figure 1 & Figure 2).

The width of the spinal nerve canal among patients of the median hernias averaged 8.13 mm ± 0.43 mm, the paramedian hernia - 6.24 mm ± 0.36 mm, and the foraminal hernia - 3.37 mm ± 0.49 mm (P<0.001) respectively. In the group of patients with disc protrusion, these parameters were: 9.07 mm ± 0.39 mm, 7.12 mm ± 0.83 mm and 4.17 mm ± 0.46 mm (P<0.01, P<0.001).

The level of lumbar discs	Protrusion (n = 73 discs)		
	Median	Paramedian	Foraminal
	1	2	3
	28 (38.4% ± 3.9%) P1-3 <0.001	36 (49.3% ± 5.9%) P2-3 <0.001	9 (12.3% ± 3.8%)
L3-L4 21 (28.8% ± 4.2%)	8 (11.0% ± 3.7%)	9 (12.3% ± 3.8%)	4 (5.5% ± 2.7%)
L4-L5 27 (37.0% ± 3.9%)	11 (15.1% ± 4.2%)	13 (17.8% ± 4.5%) P2-3 <0.01	3 (4.1% ± 2.3%)
L5-S1 25 (34.2% ± 5.4%)	9 (12.3% ± 3.8%) P1-3 <0.05	14 (19.2% ± 4.6%) P2-3 <0.01	2 (2.7% ± 1.9%)

Table 4: The level and location of lumbar discs protrusion.

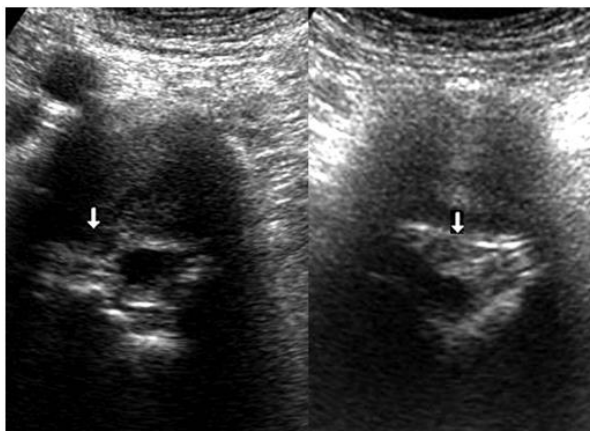


Figure 1: On the left side of the echogram, the vertical arrow shows the foraminal hernia, on the right side - a large paramedian hernia caused a spinal stenosis.

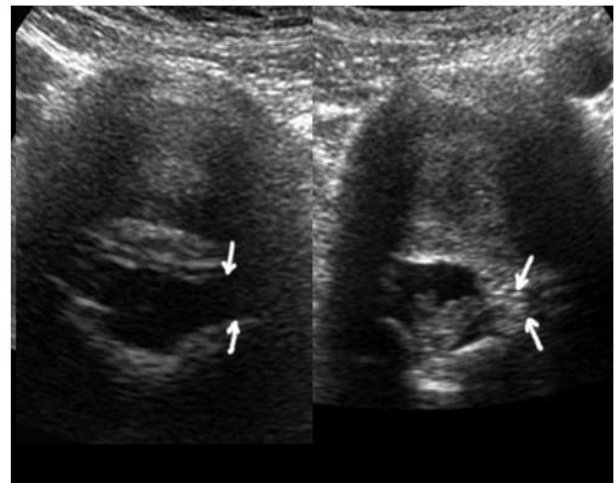


Figure 2: On the left side of the echogram, the vertical arrows show the unchanged discs and the normal channel of the spinal nerves. On the right side of the echogram, oblique arrows show a foraminal hernia and a narrowed canal of the spinal nerves.

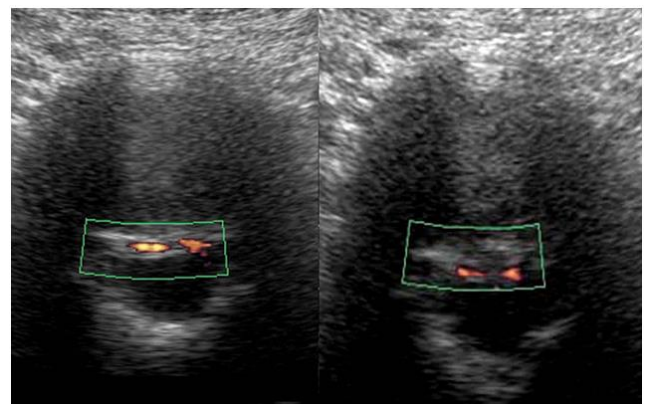


Figure 3: On the left side of the echogram, unchanged epidural veins and disc are shown, on the right side is the median hernia with mild dislocation of these veins.

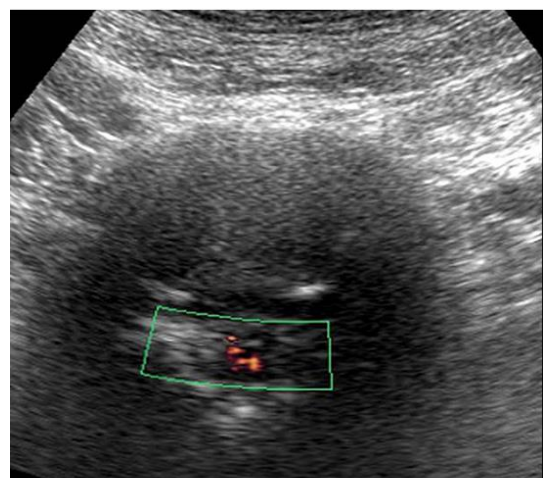


Figure 4: The large sequestering median hernia with severe spinal stenosis at the level of L5-S1 in a patient with lumbago + sciatica. Severe dislocation of epidural vessels are seen.

Disturbance of blood flow in the epidural veins was noted in the form of changes in color vascular signals (thinning, expansion, dislocation, absence). Among patients with median hernia, blood flow disorder was registered in 7 (53.8% ± 13.9%) cases, paramedian hernia - 9 (29.0% ± 8.1%) and foraminal hernia - 4 (9.5% ± 4.5%) of case (Figure 3 & Figure 4).

The comparison of the image quality of the discs by USG and MRI are presented in table 5. In total, an ultrasound examination of 159 discs was performed, MRI - of 121 discs. An excellent ultrasound image was obtained in 72 (45.3% ± 3.9%) cases, with MRI in 71 (58.7% ± 4.5%) cases (P<0.05). A good image was obtained in 74 (46.5% ± 4.0%) and 45 (37.2% ± 4.4%) cases, unsatisfactory images in 13 (8.2% ± 2.1%) and in 5 (4.1% ± 1.8%) cases, respectively (Figure 5).

The quality of image	USG (n = 159 discs)	MRI (n = 121 discs)
Excellent	72 (45.3% ± 3.9%)	71 (58.7% ± 4.5%) P<0,05
Good	74 (46.5% ± 4.0%)	45 (37.2% ± 4.4%)
Not a satisfactory	13 (8.2% ± 2.1%)	5 (4.1% ± 1.8%)

Table 5: Comparison of the image quality of the discs by USG and MRI.

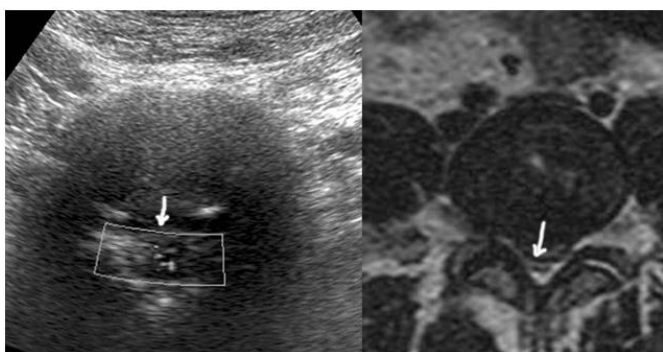


Figure 5: The large sequestering median hernia with severe spinal stenosis is detected by ultrasonography and MRI (arrows).

In 37 cases, the degenerative changes in the discs contributed to the development of spinal stenosis. 25 patients underwent laminectomy for moderate and severe spinal stenosis. In 12 (92.3% ± 7.4%) cases spinal

stenosis was caused by a median hernia, in 23 (74.2% ± 7.9%) cases by a paramedian hernia and in 2 (4.8% ± 3.2%) cases by a foraminal hernia (Table 6). As can be seen from the table severe spinal stenosis was significantly more frequent due to the median hernia (P<0.001).

Degree of stenosis	The location of the hernia (37 discs)		
	Median 12/13	Paramedian 23/31	Foraminal 2/42
Mild	1	9	2
Moderate	4 (30.8% ± 12.8%)	12 (38.7% ± 8.8%)	-
Severe	7 (53.8% ± 13.8%) P<0.001	2 (6.5% ± 4.4%)	-
Total	12 (92.3% ± 7.4%)	23 (74.2% ± 7.9%)	2 (4.8% ± 3.2%)

Table 6: The relationship between the degree of lumbar spinal stenosis and the nature of degenerative changes in intervertebral discs.

5. DISCUSSION

In this study, we matched symptoms of clinical examination with ultrasonographic findings in patients with low back pain caused with degenerative disc disease. Throughout life, approximately 60% - 90% of the population may experience back pain. The spinal segments L4-L5 and L5-S1 is the most common source of low back pain [10].

Low back pain can manifest as lumbago or sciatica. Disc herniation is the most common cause of radiculopathy by nerve root compression [16]. To evaluate the lumbar region, MRI is the investigation of choice. It is the preferred method of diagnosing and evaluating of herniated and protruded discs, compression of nerve root. Unconditionally MRI is the most common, and the image is more “understandable” for a significant majority of doctors (neurologists, orthopedists) [23]. Research by Van Rijn JC (2006) show that there is not always a correlation between clinical symptoms and MRI findings.

The results of our studies showed that ultrasound in the vast majority of cases allows you to get a good image of the lumbar discs, the central spinal canal and of the spinal

nerve canals. The use of Doppler modes will provide additional information about the state of epidural blood flow. Dopplerography of the epidural vein flow in a patient with sequestering hernias often recorded a circulatory disturbance that does not provide an MRI.

We found that foraminal hernias and protrusions cause a maximum decrease in the width of the spinal cord channel and compression of the nerve root. Our studies showed that in patients with sciatica, foraminal disc hernias at the L5-S1 level are significantly more often diagnosed. Lumbago often occurred in patients with degenerative changes in discs of median localization, more often at the level of L3-L4 and L4-L5. Spinal stenosis was significantly more often observed in patients with median localization of disc herniation.

6. CONCLUSION

The ultrasonography can be used not only as a screening for detecting degenerative changes in the discs, but also for accurate diagnosis of hernia and protrusion. The results of ultrasonography in most cases explain the clinical symptoms of back pain. It was found that sciatica more often occurs in the presence of foraminal and paramedian hernia at the level of L5-S1, severe stenosis of the spinal canal - in patients with median hernia.

7. CONFLICT OF INTEREST

The authors declared no potential conflict of interest with respect to the research, authorship, and/or publication of this article.

REFERENCES

1. Czervionke LF, Fenton DS (2011) Imaging painful spine disorders e-book. Elsevier Health Sciences. Saunders: 672.
2. Liebscher T, Haefeli M, Wuertz K, et al. (2011) Age-related variation in cell density of human lumbar intervertebral disc. *Spine* 36(2): 153-159.
3. Schollum ML, Robertson PA, Broom ND (2010) How age influences unravelling morphology of annular lamellae-a study of interfibre cohesivity in the lumbar disc. *Journal of Anatomy* 216(3): 310-319.
4. Marinelli NL, Haughton VM, Muñoz A, et al. (2009) T2 relaxation times of intervertebral disc tissue correlated with water content and proteoglycan content. *Spine* 34(5): 520-524.
5. Videman T, Gibbons LE, Battié MC (2008) Age-and pathology-specific measures of disc degeneration. *Spine* 33(25): 2781-2788.
6. Brown KR, Pollintine P, Adams MA (2008) Biomechanical implications of degenerative joint disease in the apophyseal joints of human thoracic and lumbar vertebrae. *American Journal of Physical Anthropology: The Official Publication of the American Association of Physical Anthropologists* 136(3): 318-326.
7. Al-Rawahi M, Luo J, Pollintine P, et al. (2011) Mechanical function of vertebral body osteophytes, as revealed by experiments on cadaveric spines. *Spine* 36(10): 770-777.
8. Adams MA, Stefanakis M, Dolan P (2010) Healing of a painful intervertebral disc should not be confused with reversing disc degeneration: Implications for physical therapies for discogenic back pain. *Clinical Biomechanics* 25(10): 961-971.
9. Takashima H, Takebayashi T, Yoshimoto M, et al. (2012) Correlation between T2 relaxation time and intervertebral disk degeneration. *Skeletal Radiology* 41(2): 163-167.
10. Baliga S, Treon K, Craig NJA (2015) Low back pain: Current surgical approaches. *Asian Spine Journal* 9(4): 645-657.
11. Kordi R, Rostami M (2011) Low back pain in children and adolescents: An algorithmic clinical approach. *Iranian Journal of Pediatrics* 21(3): 259-270.

12. de Schepper EI, Damen J, van Meurs JB, et al. (2010) The association between lumbar disc degeneration and low back pain: The influence of age, gender, and individual radiographic features. *Spine* 35(5): 531-536.
13. Adams MA, Dolan P (2012) Intervertebral disc degeneration: Evidence for two distinct phenotypes. *Journal of Anatomy* 221(6): 497-506.
14. Fagan AB, Sarvestani G, Moore RJ, et al. (2010) Innervation of annulus tears: An experimental animal study. *Spine* 35(12): 1200-1205.
15. Olmarker K (2008) Puncture of a lumbar intervertebral disc induces changes in spontaneous pain behavior: An experimental study in rats. *Spine* 33(8): 850-855.
16. Fardon DF, Williams AL, Dohring EJ, et al. (2014) Lumbar disc nomenclature: Version 2.0: Recommendations of the combined task forces of the North American Spine Society, the American Society of Spine Radiology and the American Society of Neuroradiology. *The Spine Journal* 14(11): 2525-2545.
17. Benson RT, Tavares SP, Robertson SC, et al. (2010) Conservatively treated massive prolapsed discs: A 7-year follow-up. *The Annals of The Royal College of Surgeons of England* 92(2): 147-153.
18. Gilbert FJ, Grant AM, Gillan MG, et al. (2004) Low back pain: Influence of early MR imaging or CT on treatment and outcome-multicenter randomized trial. *Radiology* 231(2): 343-351.
19. Kreiner DS, Hwang SW, Easa JE, et al. (2014) An evidence-based clinical guideline for the diagnosis and treatment of lumbar disc herniation with radiculopathy. *The Spine Journal* 14(1): 180-191.
20. Ultrasonography S (2016) United Health care Commercial Medical Policy. Proprietary Information of United Health care. Copyright 2016 United HealthCare Services. Inc. Effective 8(01).
21. Abdullaev RY, Kalashnikov VI, Ibragimova KN, et al. (2017) The role of two-dimensional ultrasonography in the diagnosis of protrusion of cervical intervertebral discs in adolescents. *American Journal of Clinical and Experimental Medicine* 5(5): 176-180.
22. Karmakar MK, Li JW, Kwok WH, et al. (2013) Sonoanatomy relevant for lumbar plexus block in volunteers correlated with cross-sectional anatomic and magnetic resonance images. *Regional Anesthesia & Pain Medicine* 38: 391-397.
23. van Rijn JC, Klemetso N, Reitsma JB, et al. (2006) Symptomatic and asymptomatic abnormalities in patients with lumbosacral radicular syndrome: Clinical examination compared with MRI. *Clinical Neurology and Neurosurgery* 108(6): 553-557.