

## Rare Location of a Melanoma

Mennouni MA, Oukessou Y, Wilfrid L, Rouadi S, Abada R, Roubal M and Mahtar M

*ORL Consultation Center, Morocco*

Correspondence should be addressed to Mohamed Amine Mennouni, [medamine.mennouni@gmail.com](mailto:medamine.mennouni@gmail.com)

Received: October 10, 2020; Accepted: November 07, 2020; Published Date: November 16, 2020

### **ABSTRACT**

Primary oral melanoma is an extremely rare tumor which accounts for 0.2 to 8.0% of all melanoma cases and 0.5% of all malignant tumors in the mouth. It has an aggressive behavior with a dark prognosis. The survival rate at 5 years between 5 and 20% [1,2]. Early symptoms often go undetected, resulting in late diagnosis and worsening of the prognosis. Because of its rarity, there are no well-defined classification and therapeutic protocol. Early diagnosis and treatment is essential to improve the survival rate.

We present a case of palate melanoma affecting a 52-year-old woman with no medical history. We wish to emphasize the importance of early and accurate detection of melanoma of the oral cavity for its positive influence on therapeutic outcomes.

### **KEYWORDS**

Oral mucosal; Melanoma; Palate surgery.

### **INTRODUCTION**

Malignant melanoma is a malignant tumor with a very poor prognosis. Oral cavity location is rare, oral mucosa is least affected by less than 1% of all melanomas, with preferential location in the maxillary and maxillary mucosa, and less frequently in the palate mucosa [1]. This tumor, although rare, remains very aggressive, a complex treatment and an unfavorable prognosis as our case illustrates. It requires a precise pre-therapeutic evaluation (imaging) and codification, covering in principle an essentially surgical management complemented by radiotherapy, preferably in a multidisciplinary setting.

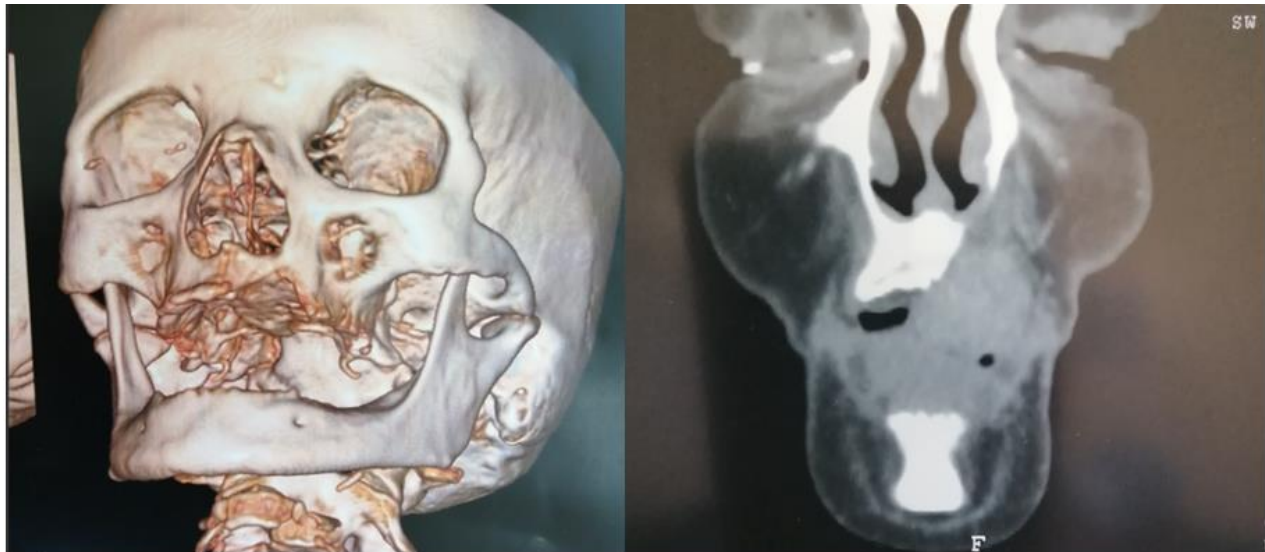
### **OBSERVATION**

In our case, this is a 52-year-old woman with no family history of melanoma. The patient puts a dental prosthesis 4 months before the appearance of the lesion. The patient consulted a general practitioner in February 2019 for pain in the bony palate and then the patient was sent to us for additional care.

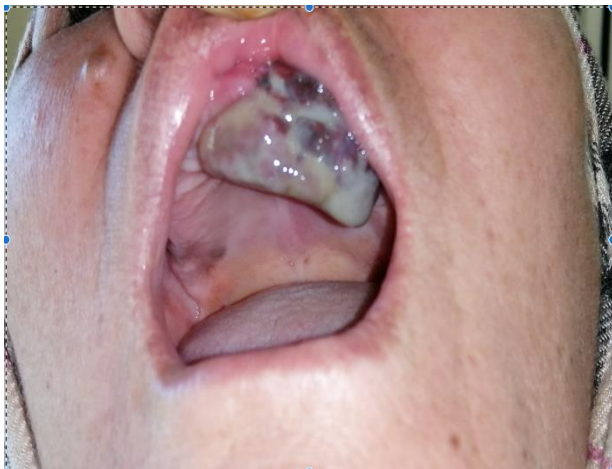The clinical examination showed a blackish gingival mass with a length of 4 cm long axis, poorly limited, painful on palpation, non-bleeding on contact, localized in the left bony palate infiltrating the left maxillary left and the left gingival mucosa and exceeding the median line. No other pigmentation or unusual lesions were present in other oral locations or on the lips, the rest of

**Citation:** Mohamed Amine Mennouni, Rare Location of a Melanoma. Clin Surg J 4(S5): 5-8.

the examination was normal. (Figure 1). Facial scanner shows a tissue mass with bone lysis in the upper left maxilla (Figure 2).



**Figure 1:** Gingival mass.



**Figure 2:** Facial scanner shows a tumor.

A tumor extension assessment was done the PET-scan and cervical thoracic scan were normal. For this a surgical management was chosen.

## **DISCUSSION**

Primary malignant melanoma of the oral cavity is a rare malignant tumor that develops from pigment cells derived from neural ridges. Oral melanomas account for 0.4 to 8% of all melanoma tumors [2,3]. They reach more the man between 50 and 60 years old, and develop mainly on the palatal mucosa, the gum, the lips. The

A biopsy of the mass was done under local anesthesia. Anatomico-pathological examination confirmed the histological diagnosis of melanoma.

etiopathogenesis remains unknown, although there is a genetic predisposition but no well-defined precursor has been isolated. Repetitive strain injuries on a pre-existing benign nevus have also been implicated as well as other risk factors such as tobacco and alcohol. The evolution of melanoma is in two phases: first horizontally, then vertically.

The clinical diagnosis is evoked before a nodule or a closet more or less extended, of non-homogeneous color, ranging from light brown to anthracite black, with irregular surface, often ulcerated and haemorrhagic [4].

Anatomico-pathological examination confirms the diagnosis in the presence of 3 criteria considered specific: the appearance of tumor cells (4 possible types: pseudo-epithelial, fusiform, undifferentiated or mixed), the existence of a junctional activity and the presence of melanin in tumor cells. In the achromic forms, the use of immunohistochemistry is essential [5].

The differential diagnosis of melanoma is done with an amalgam tattoo, a physiological or smoking

pigmentation, a post-extracorporeal granuloma, or a melanoacanthoma. [2,6]

The extension assessment includes a cervicofacial or MRI scanner, a thoracoabdominal CT scan, a bone scans and possibly a PET scan. Only histology and immunocytochemical analysis confirm the diagnosis and eliminate other differential diagnoses. The most commonly used markers are S100, HMB45 and Melan-A [7]. Surgery is the first-line treatment, see the only effective treatment in some patients, tumor excision should be wide and the limits of excision are controlled by an extemporaneous pathological examination [8].

Although surgery is the most effective therapeutic method, it is made difficult by anatomical constraints. According to some authors melanomas of the oral cavity are very lymphophile: there are metastatic lymph nodes in 20% of cases [6,8].

Some authors advocate a systematic lymph node dissection while for others, it is only indicated in front of the confirmed presence of metastatic lymph nodes [1,8] but the role of lymph node recess is not yet evaluated because of the scarcity of the tumor and the dark prognosis [9]. Some are determined according to the sentinel lymph node: this first ganglionic relay can be detected by injection of methylene blue or a radiator around the melanoma. After locating, the ganglion is removed and examined histologically: dissection is considered only if a metastasis or micrometastasis is detected [10].

Radiation therapy will be used in combination with surgery or only inoperable patients. It is proposed postoperatively because of the high frequency of local recurrence after surgery. The total dose administered is between 50 and 70 Gy, requiring high doses of at least 4 Gy per session and a total dose of at least 50 Gray.

The field of irradiation concerns the tumor site and the lymph nodes [11,12]. Adjuvant treatments are particularly indicated for very large tumors. Chemotherapy (procarbazine) and immunotherapy (cytokines, interferon alpha, interleukins) have only been shown to be effective in metastatic forms. The prognosis of melanoma is variable according to the different anatomoclinical forms and localization. It is worse for oral melanoma because, in the absence of functional signs, the discovery is often late, that is to say in the vertical invasion phase, often after it has already invaded the deep chorion and Ships. The diagnosis of achromic melanoma is often very difficult, making the prognosis even worse [13,14]. The 5-year survival of patients with melanoma of the oral cavity is mediocre, it remains between 5 and 20% according to the authors [13]. The evolution is dominated by the presence of distant metastasis mainly pulmonary, mediastinal, cerebral, hepatic, bone and more rarely adrenal, thyroid, pancreatic and cutaneous [15,16], and which remain unpredictable and difficult to control.

In our case, the patient had a conservative surgery associated with radiotherapy was chosen. The surgical excision was as wide as possible, passing at least 1 cm from the tumor boundaries. This radical surgery offers the best chance of survival for the patient [17,18]. Lymph node dissection was not done in our case because of the absence of clinical and radiological lymph node metastasis.

## **CONCLUSION**

Although rare, the diagnosis of malignant melanoma must be made before any pigmented lesion of the oral mucosa, especially palatal or superior gingival tissue. Computed tomography is essential for the assessment of extension. An assessment of extension of the search for metastasis is essential to define the behavior to hold. The early diagnosis of the tumor is extremely important and could optimize the prognosis of the patient.

## **REFERENCES**

1. Aguas SC, Quarracino MC, Lence AN, et al. (2009) Primary melanoma of the oral cavity: Ten cases and review of 177 cases from literature. *Oral Medicine, Oral Pathology and Oral Surgery* 14(6): E265-271.
2. Haïtami S, Yahya IB, Kinani L, et al. (2011) Melanoma of the oral cavity: presentation of 3 cases. *Journal of Oral Medicine and Oral Surgery* 17(4): 271-277.
3. Hicks MJ, Flaitz CM (2000). Oral mucosal melanoma: Epidemiology and pathobiology. *Oral Oncology*, 36(2) 152-169.
4. Patel SG, Prasad ML, Escrig M, et al. (2002) Primary mucosal malignant melanoma of the head and neck. *Head & Neck: Journal for the Sciences and Specialties of the Head and Neck* 24(3): 247-257.
5. Chang AE, Karnell LH, Menck HR (1998) The National Cancer Data Base report on cutaneous and noncutaneous melanoma: A summary of 84,836 cases from the past decade. *Cancer: Interdisciplinary International Journal of the American Cancer Society* 83(8): 1664-1678.
6. Hicks MJ, Flaitz CM (2000) Oral mucosal melanoma: epidemiology and pathobiology. *Oral Oncology* 36(2):152-169.
7. Dimitrakopoulos I, Lazaridis N, Skordalaki A (1998) Primary malignant melanoma of the oral cavity Report of an unusual case. *Australian Dental Journal* 43(6): 379-381.
8. Buchner A, Merrell PW, Carpenter WM (2004) Relative frequency of solitary melanocytic lesions of the oral mucosa. *Journal of Oral Pathology & Medicine* 33(9): 550-557.
9. Meleti M, Leemans CR, Mooi WJ, (2007) Oral malignant melanoma: the Amsterdam experience. *Journal of Oral and Maxillofacial Surgery* 65(11): 2181-2186.
10. Rapis AD, Apostolidis C, Vilos G, et al. (2003) Primary malignant melanoma of the oral mucosa. *Journal of Oral and Maxillofacial Surgery* 61(10): 1132-1139.
11. Meleti M, Leemans CR, Mooi WJ, et al. (2007) Oral malignant melanoma: a review of the literature. *Oral Oncology* 43(2): 116-121.
12. Umeda M, Shimada K (1994) Primary malignant melanoma of the oral cavity - Its histological classification and treatment. *British Journal of Oral and Maxillofacial Surgery* 32(1): 39-47.
13. Tanaka N, Mimura M, Ogi K, et al. (2004) Primary malignant melanoma of the oral cavity: assessment of outcome from the clinical records of 35 patients. *International Journal of Oral and Maxillofacial Surgery* 33(8): 761-765.
14. Vallicioni J, Rodríguez J, Buisset E, et al. (1991) Malignant melanomas of a facial mass. Experience of the ENT group of cancer centers. *Head and Neck Carcinology* 17.
15. González-García R, Naval-Gías L, Martos PL, et al. (2005) Melanoma of the oral mucosa. Clinical cases and review of the literature. *Oral Medicine, Oral Pathology and Oral Surgery* 10(3): 264-271.
16. Garzino-Demo P, Fasolis M, Maggiore GMLT, et al. (2004) Oral mucosal melanoma: a series of case reports. *Journal of Cranio-Maxillofacial Surgery* 32(4): 251-257.
17. Temam S, Mamelle G, Marandas P, et al. (2005) Postoperative radiotherapy for primary mucosal melanoma of the head and neck. *Cancer* 103(2): 313-319.
18. Haïtami S, Yahya IB, Kinani L, et al. (2011) Melanoma of the oral cavity: Presentation of 3 cases. *Journal of Oral Medicine and Oral Surgery* 17(4): 271-277.