

Practique Clinique et Investigation

Pattern of Carotid Plaques in Patients with Transient Ischemic Attack or Ischemic Stroke

Emmanuel Auchi Edafe^{1*} | Narendra Nath Khanna¹ | Dodo Peter Yakubu¹ | Suparna Rao¹ | Arthur Chukwubike Onwuchekwa²

¹Department of Interventional Cardiology, Indraprastha Apollo Hospital, New Delhi, India

²Department of Internal Medicine, University of Port Harcourt Teaching Hospital, Port Harcourt, Nigeria

*Correspondence: Emmanuel Auchi Edafe, Consultant Interventional cardiology, Cardiology Unit, Bayelsa Specialist Hospital, Yenagoa, E-mail: dremmanueledafe@gmail.com

ABSTRACT

Introduction: Atherosclerosis is a chronic disease affecting the medium and large arteries. A Plaque is a build-up of atherosclerotic lesions. Gray-Waele classified plaques into type 1 to 4. Plaque may be identified in the ultrasound image. it may be homogeneous or heterogeneous. The objective of this study was to analyze the ultrasonography (US) characteristics of the carotid plaques in patients with TIA or ischemic stroke who presented for carotid angioplasty plus stenting. The focus was on the pattern of plaque characteristics as in modified Gray-Waele classification, plaque surface, and ulceration.

Methods: A retrospective review of 27 patients with history TIA or stroke corresponding to the carotid artery territory in the brain. These patients presented to the Apollo Heart Institute, New Delhi for carotid angioplasty and stenting. This review covered from 1st January 2015 to 31st December 2017.

Results: A total of 27 patients with male 19 (70.4%) and female 8 (29.6%). Gray-Wale type 1 account for 48% (n=13), type 2 was 41% (n=11), and type 3 account for 7 (n=2).

Conclusion

Gray-Waele Type 1 and 2 are the most common cause of TIA or ischemic stroke. Irregular and heterogeneous plaque patients are at higher risks for cerebrovascular events, and most lesions involved the bifurcations.

Keywords: *Carotid plaque; Transient ischemic attack; Ischemic stroke*

INTRODUCTION

The American Heart Association and the American Stroke Association in 2013 defined stroke as clinical syndrome typified by rapidly evolving focal disturbance of cerebral function, of vascular origin with an objective neuroimaging evidence of a

Citation: Emmanuel A Edafe, Pattern of Carotid Plaques in Patients with Transient Ischemic Attack or Ischemic Stroke. *Prac Clin Invest* 3(2): 61-67.

©2021 Tridha Scholars

lesion irrespective of the duration of clinical symptoms. This definition included tissue-based due to technological advancement in stroke diagnosis and therapy. It also brought out the concept of silent strokes.

The American Heart Association and the American Stroke Association in 2009 defined TIA as transient neurological dysfunction caused by focal brain, spinal cord, or retinal ischemia without any objective evidence of an acute infarction. Again, this definition eliminates the benign connotation of transient ischemic attack.

Atherosclerosis is a chronic disease affecting the medium and large arteries. A Plaque is a build-up of atherosclerotic lesions. Gray Waele classified plaques into type 1 to 4 [1]. Plaque may be identified on the ultrasound image. It may be homogeneous or heterogeneous. In this study, we retrospectively evaluated carotid plaques pattern in patients with stroke or TIA who presented to the Apollo Heart Institute, New Delhi for carotid angioplasty plus stenting, using B-mode ultrasound.

The objective of this study was to analyze the ultrasonography (US) characteristics of the carotid plaques in patients with TIA or ischemic stroke who presented for carotid angioplasty plus stenting. The focus was on the pattern of plaque characteristics as in modified Gray-Waele classification, plaque surface, and ulceration.

METHODS

A retrospective review of 27 patients with history TIA or stroke corresponding to the carotid artery territory in the brain. These patients presented to the Apollo Heart Institute, New Delhi for carotid angioplasty and stenting. This review covered from 1st January 2015 to 31st December 2017. Carotid ultrasound was done for these 27 patients with GE ultrasound equipped with 8L or 3S probes before carotid angiography, and angioplasty with stenting. Excluded are hemorrhagic stroke and patients with ischemic stroke with hemorrhagic transformation.

DEFINITIONS OF TERMS

1. Regular plaque: A plaque is regular when the blood-lesion interface is smooth and unbroken.
2. Irregular plaque: A plaque is irregular when there is a break in the echo-reflective surface of the lesion is observed or the surface is uneven.
3. Carotid plaque ulceration using color flow Doppler as a plaque niche filled with reversed flow on longitudinal views.
4. A carotid plaque was defined as a localized protrusion of the vessel wall, which extended into the lumen ≥ 1.5 mm, or had a thickness exceeding the intima-media thickness (IMT) of the adjacent portion of the vessel wall by $>50\%$. The characteristics of the plaques were described by the modified Gray Weale classification and plaque morphology was defined in terms of its echogenicity.
5. In a refinement of this classification system introduced by Gray-Weale et al. [1] in 1988, four plaque types were defined based on the degree of echolucency visualized on B-mode scan:
 - Type 1: Predominantly echolucent with a thin echogenic cap
 - Type 2: Intermediate echolucent lesions with small areas of echogenicity
 - Type 3: Intermediate echogenic lesions with small areas of echolucency ($<25\%$)
 - Type 4: Uniformly echogenic lesions (equivalent to homogenous)

DATA ANALYSIS

Retrieved data was analyzed using Statistical Package for Social Sciences (SPSS) version 20. Categorical variables were summarized as frequency and percentages and presented as graphs, while mean and standard deviation were used to characterize the distribution of continuous variables.

RESULTS

A total of 27 patients with male 19 (70.4%) and female 8 (29.6%). Diabetes mellitus with stroke or TIA was 48.1% (n=13), hypertensive with ischemic stroke or TIA were 56.5% (n=15), Dyslipidemia with stroke, or TIA=70.4% (n=19), and Smokers with TIA or stroke were 18.5% (n=5). The mean age of distribution was 66.57 ± 7.63 with ranges from 55 to 80 years (Table 1 and Table 2).

Gray-Wale type 1 account for 48% (n=13), type 2 was 41% (n=11), and type 3 account for 7 (n=2) (see Figure 1). The ultrasound characteristics of the 27 patients concerning the plaque surface, ulceration, and centricity are shown in Table 3. Most lesions involved the bifurcations.

Country of Origin	Frequency (%)
Afganistan	3(11.1%)
Iraq	1(3.7%)
India	8(29.6%)
Nepal	4(14.8%)
Bangladesh	3(11.1%)
Somalia	2(7.4%)
Madagascar	3(11.1%)
Ethiopia	1(3.7%)
Yemen	1(3.7%)
Kenya	1(3.7%)

Table 1: Country of origin.

Variable	Summary Statistics
Sex	Frequency (%)
Male	19(70.4)
Female	8(29.6)

Table 2: Sex distribution.

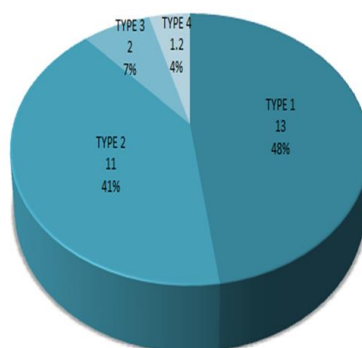


Figure 1: Plaques Types.

Plaque Characteristics	Stroke (%)	Tia (%)
Surface		
Irregular	6(54.5)	5(45.5)
Smooth	1(6.2)	15(93.8)
Ulceration		
Yes	3(60.0)	2(40.0)
No	4(18.2)	18(81.8)
Centricity		
Eccentric	7(46.7)	8(53.3)
Concentric	0(0.0)	12(100.0)

Table 3: Ultrasound Characteristics.

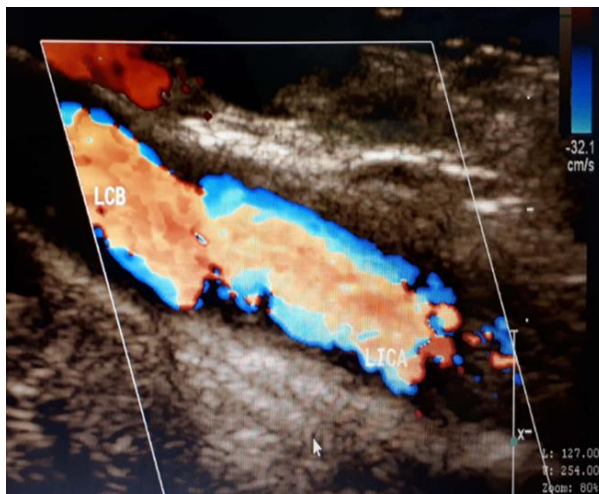


Figure 2: Type 1 Gray-Waele. See the blue arrow.

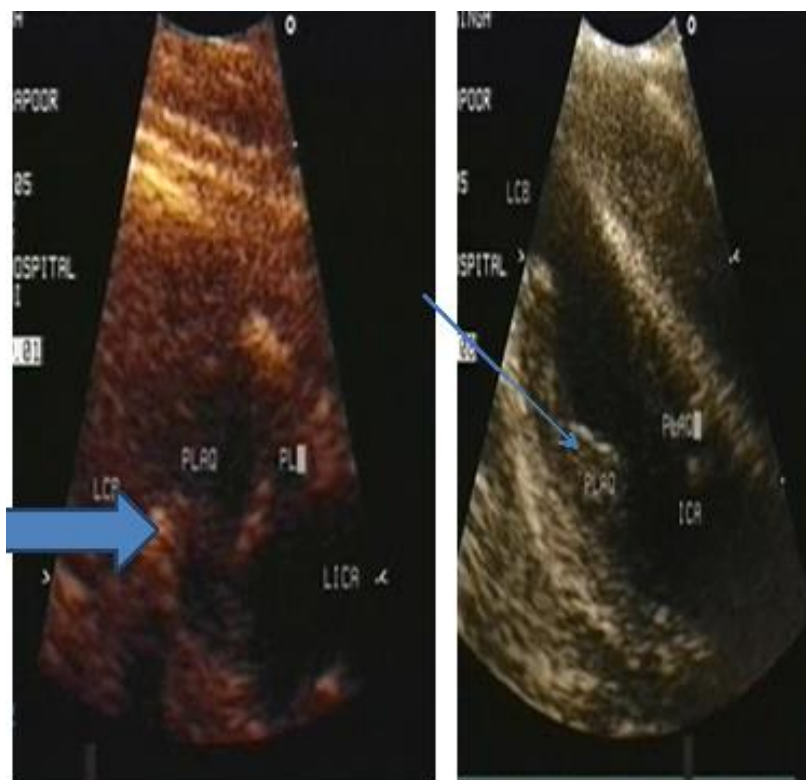


Figure 3: Type 2 Gray-Waele. See the blue arrow.

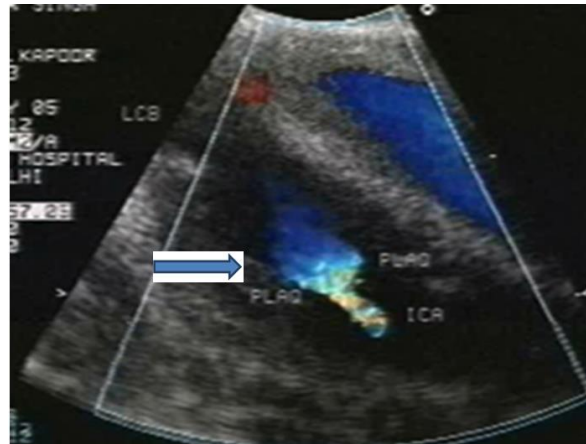


Figure 4: Type 2 Gray-Waele. The blue arrow.

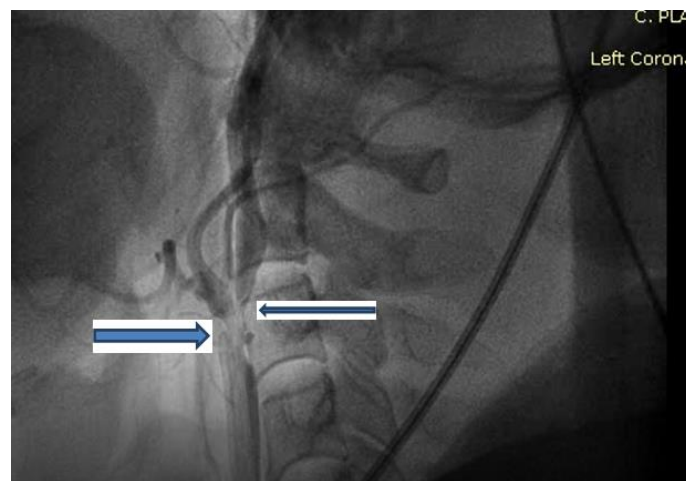


Figure 5: Carotid artery stenosis of bifurcation of the common carotid artery. This is one of the patients during carotid stenting.

DISCUSSION

The first study on carotid plaques was by Johnson et al. [2] in 1985. They followed up 297 asymptomatic patients for 3 years and showed that TIA or strokes occurred in 75% of those whose plaques had been hypo or anechoic (type 1 and 2) at baseline, as opposed to only 4.4% whose plaques had appeared hyperechoic [2]. Our review showed that TIA or ischemic stroke is more common in type 1 or 2 plaques.

Langsfeld et al. [3] studied 419 patients with asymptomatic plaques for 15-22 months and found anechogenic plaques to be at increased risk of becoming symptomatic compared with dense and echo rich plaques. O'Holleran et al. [4] followed up 293 patients for an average of 46 months and showed that 100% of the patients with a soft lesion involving >75% stenosis became symptomatic as compared with only 60% of those with a dense plaque ($p > 0.05$) [4]. Fitzgerald and O'Farrel [5] also found an irregular surface to be associated with the development of MACE.

European Carotid Plaque Study Group findings showed that [6,7]:

1. Carotid plaque echogenicity on B-mode imaging was inversely correlated with the "soft" material contained in the plaque.
2. Plaque hyperechogenicity directly correlated with the presence of calcifications.

3. Most symptoms of cardiovascular disease were reported by patients with the “softest” plaques.

Mathiesen et al. [8] reported that in patients with type 1 or type 2 plaques but no carotid stenosis, the relative risk (RR) for cerebrovascular events was 13 (95% CI 4.5-37.4) versus only 3.7 (95% CI 0.7-18.2) in those with type 3 or type 4 plaques. Reiter et al. [9] followed 574 patients for a mean of 3.2 years to determine whether those with hypoechoic or anechoic plaques were at risk for major adverse cardiovascular events (MACEs). They showed that the presence of a hypoechoic plaque predicted a MACE. This emphasizes that type 1 or 2 are vulnerable plaques. Spence showed carotid artery plaque morphology and IMT are expressions of different biological aspects of atherosclerosis with different implications in terms of vascular disease [10].

Compared with the IMT, carotid plaque morphology and surface area are both better predictors of stroke, myocardial infarction, and cardiovascular death [11-13]. This was shown in our study that demonstrated type 1 and 2 predominantly causing TIA or ischemic stroke. Our study also showed that irregular and heterogeneous plaque patients are at higher risks for cerebrovascular events.

CONCLUSION

Gray-Waele Type 1 and 2 are the most common cause of TIA or ischemic stroke. Irregular and heterogeneous plaque patients are at higher risks for cerebrovascular events, and most lesions involved the bifurcations.

LIMITATION

1. Two sonographers were involved in the carotid scan. This may introduce bias as ultrasound is observer depended.
2. Some number of patients

DECLARATION OF PATIENT CONSENT

The authors certify that they have obtained all appropriate patient consent forms. In the form, the patient(s) has/have given his/her/their consent for his/her/their images and other clinical information to be reported in the journal. The patients understand that their names and initials will not be published

FINANCIAL SUPPORT AND SPONSORSHIP

Nil

CONFLICTS OF INTEREST

There are no conflicts of interest.

REFERENCES

1. Gray-Weale AC, Graham JC, Burnett JR, et al. (1988) Carotid artery atheroma: comparison of preoperative B-mode ultrasound appearance with carotid endarterectomy specimen pathology. *The Journal of Cardiovascular Surgery* 29(6): 676-681.

2. Johnson JM, Kennelly MM, Descare D, et al. (1985) Natural history of asymptomatic carotid plaque. *Archives of Surgery* 120(9): 1010-1012.
3. Langsfeld M, Gray-Weale AC, Lusby RJ (1989) The role of plaque morphology and diameter reduction in the development of new symptoms in asymptomatic carotid arteries. *Journal of Vascular Surgery* 9(4): 548-557.
4. O'Holleran LW, Kennelly MM, Mc Clurken M, et al. (1987) Natural history of asymptomatic carotid plaque. Five year follow-up study. *The American Journal of Surgery* 154(6): 659-662.
5. O'Farrell CM, FitzGerald DE (1993) Prognostic value of carotid ultrasound lesion morphology in retinal ischaemia: result of a long term follow up. *The British Journal of Ophthalmology* 77(12): 781-784.
6. European Carotid Plaque Study Group (2011) Reprinted article "carotid artery plaque composition-relationship to clinical presentation and ultrasound B-mode imaging". *European Journal of Vascular and Endovascular Surgery* 42(1): 32-38.
7. Golledge J (2011) Commentary on: reprinted article "carotid artery plaque composition-relationship to clinical presentation and ultrasound B-mode imaging". *European Journal of Vascular and Endovascular Surgery* 42: 39-40.
8. Mathiesen EB, BØnaa KH, Joakimsen O (2001) Echolucent plaque are associated with high risk of ischemic cerebrovascular events in carotid stenosis: the TromsØ study. *Circulation* 103(17): 2171-2175.
9. Reiter M, Effenberger I, Sabeti S, et al. (2008) Increasing carotid plaque echolucency is predictive of cardiovascular events in high-risk patients. *Radiology* 248(3): 1050-1055.
10. Spence JD (2010) The role of lipoprotein(a) in the formation of arterial plaques, stenoses and occlusions. *The Canadian Journal of Cardiology* 26(Suppl): 37-40.
11. Prati P, Tosetto A, Casaroli M, et al. (2011) Carotid plaque morphology improves stroke risk prediction: usefulness of a new ultrasonographic score. *Cerebrovascular Diseases* 31(3): 300-304.
12. Mathiesen EB, Johnsen SH, Wilsgaard T, et al. (2011) Carotid plaque area and intima-media thickness in prediction of first-ever ischemic stroke: a 10-year follow-up of 6584 men and women: The TromsØ study. *Stroke* 42(4): 972-978.
13. Inaba Y, Chen JA, Bergmann SR (2012) Carotid plaque, compared with carotid intima-media thickness, more accurately predicts coronary artery disease events: a meta-analysis. *Atherosclerosis* 220(1): 128-133.