

## Pathology of Ankle Joint and Knee as a Result of Permanent Distortion Syndrome in Car Drivers and Passengers

Karski Jacek<sup>1</sup>, Karski Tomasz<sup>2</sup>, Karska Klaudia<sup>3</sup>, Karska Katarzyna<sup>1</sup>, Menet Honorata<sup>4</sup> and Pyrc Jaroslaw<sup>5</sup>

<sup>1</sup>Medical University in Lublin, Poland

<sup>2</sup>Vincent Pol University in Lublin, Poland

<sup>3</sup>Children Radiology Department of Medical University in Lublin, Poland

<sup>4</sup>University in Caen, France

<sup>5</sup>Department of Trauma and Orthopedic Surgery, Elblandkliniken Radebeul, Germany

Correspondence should be addressed to Tomasz Karski, [tmkarski@gmail.com](mailto:tmkarski@gmail.com)

Received: November 04, 2020; Accepted: November 22, 2020; Published Date: November 30, 2020

### **ABSTRACT**

Deformations of the feet of the children and feet pain syndromes of adults are very common, more likely to appear in Europe in women. In children and youth we can observe:

1. Valgus or Plano- valgus feet deformity and there are congenital or connected with neurological dysfunction of feet.
2. Köhler's disease among girls wearing improper shoes.

Among adults can appear:

1. Insufficiency and pain of the frontal part of feet connected with limited toes flexion
2. Valgus deformity of the big toes (hallux valgus),
3. "Pain Syndrome of Ankle Joint" (PSofAJ) – sometimes also "Pain Syndrome of Knee Joint" (PSof KJ) – described by us only in the USA and in Czech Republic.

The "pain syndromes" is due to the instability of these joints. In our study, we describe this special type of foot insufficiency - "instability of ankle or knee, or both

joints" and pain syndrome as a result of "permanent distortion" - on left leg in drivers and right leg in passengers in countries with right-hand traffic. This paper focuses on the foot.

### **KEYWORDS**

Chronic distortion of the ankle joint and knee; Chronic pain syndrome

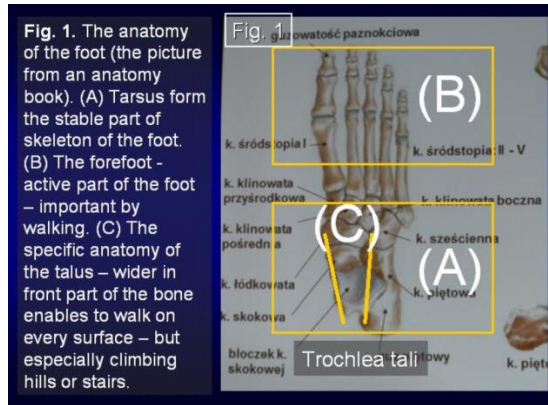
### **INTRODUCTION**

#### *Foot ankle joint anatomy*

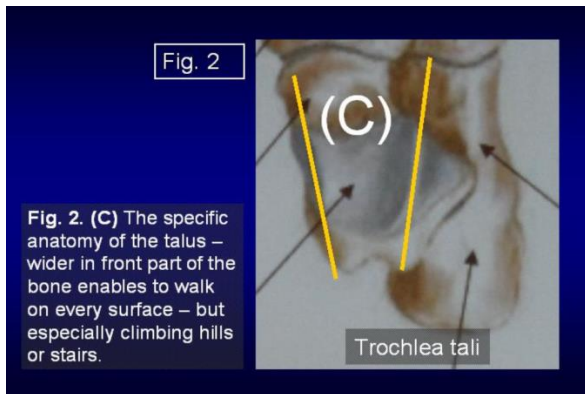
There are two important parts in the foot. Back part tarsus important in standing. Front part- important in walking, jumping, running (Figure 1 & Figure 2). In ankle joint there are two movements- dorsal and plantar flexion. In sub - talo part of the foot there is supination, pronation, and flexion of the toes. Upper part of the talus - sustentaculi tali - is wider in the front than in the back. It is important for climbing stairs or hills. The talus is situated between two malleoli - coming from the tibia and from the fibula. Only two malleoli coming from two bones- enable good functioning in everyday situations. If

**Citation:** Tomasz Karski, Pathology of Ankle Joint and Knee as a Result of Permanent Distortion Syndrome in Car Drivers and Passengers. Clin Surg J 4(S6): 1-5.

both malleoli were coming from one bone, from the tibia - it would cause difficulties- not a proper adaptation of joint surfaces, arthrosis, pain, difficulty walking and doing other activities.



**Figure 1:** The anatomy of the foot (the picture from an anatomy book). (A) Tarsus form the stable part of skeleton of the foot. (B) The forefoot - active part of the foot - important by walking. (C) The specific anatomy of the talus - wider in front part of the bone enables to walk on every surface- but especially climbing hills or stairs.

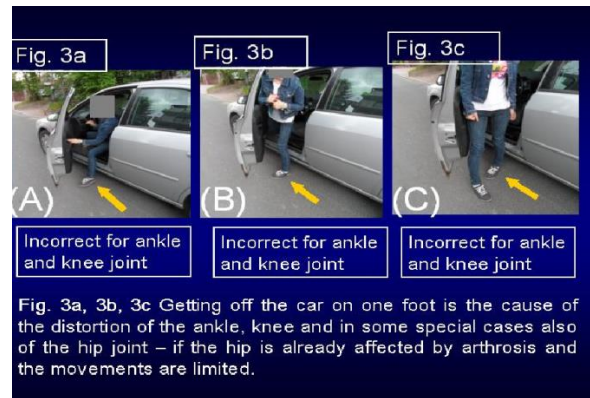


**Figure 2 (C):** The specific anatomy of the talus- wider in front part of the bone enables to walk on every surface- but especially climbing hills or stairs.

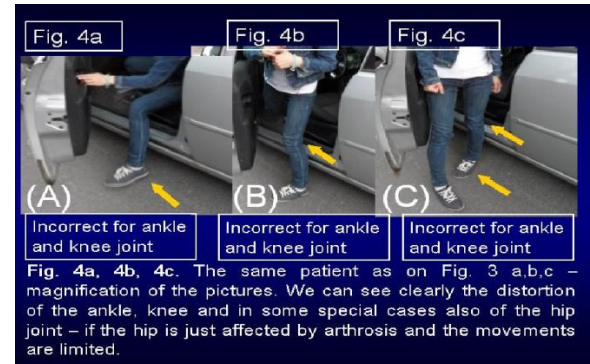
### Cause of instability of ankle joint and knee

We found that getting out of the car - on one leg - on one foot - causes such instability - mostly in the ankle joint, but in some patients in the knee (Figure 3a, 3b, 3c and Figure 4a, 4b, 4c and Figure 5). Both joints have only two movements - flexion and extension and every rotation movement is pathological. The problem of left foot has been observed in drivers, and of the right foot passengers. It applies to Poland, Germany and France, right-hand traffic countries. The syndrome of ankle and

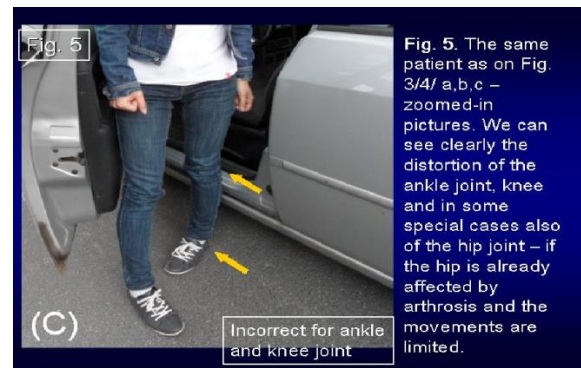
knee instability and pain in some patients can be caused by their work or by the everyday chores.



**Figure 3A, 3B, 3C:** Getting off the car on one foot is the cause of the distortion of the ankle, knee and in some special cases also of the hip joint - if the hip is already affected by arthrosis and the movements are limited.



**Figure 4A, 4B, 4C:** The same patient as on Figure 3A, 3B, and 3C - magnification of the pictures. We can see clearly the distortion of the ankle, knee and in some special cases also of the hip joint- if the hip is just affected by arthrosis and the movements are limited.

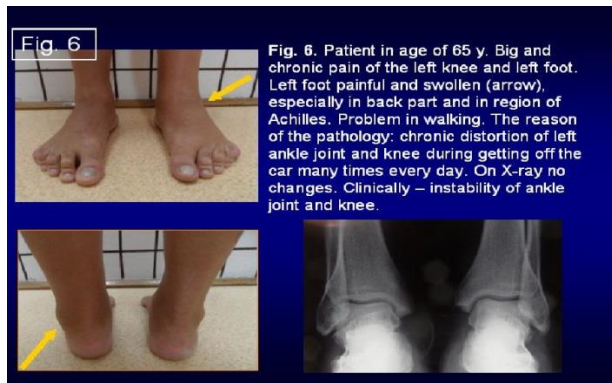

**Figure 5:** The same patient as on Figure 3A, 3B, 3C and Figure 4A, 4B, 4C - zoomed-in pictures. We can see clearly the distortion of the ankle joint, knee and in some special cases also of the hip joint - if the hip is already affected by arthrosis and the movements are limited.

### Diagnosis

We should prove the range of dorsal flexion of foot, stability in talo - tibial joint, stability of the knee joint - of

lateral ligaments and ligaments cruciatum. In pathology, we observe loss of stability. Sometimes during examination of stabilization, ‘knocking’ sound of tibial and femur condyli can be heard. In many patients we see swelling in the back part of the foot and in the Achilles tendon region, pain while moving the foot and considerable limitation of dorsal flexion of the affected foot. Many patients limp. Some patients try to walk “on toes” - in the maximal plantar flexion of feet. It diminishes the pain, but it is not an efficient “method of treatment”. After walking in such a way for several days, patients seek medical advice (Figure 6).



**Fig. 6.** Patient in age of 65 y. Big and chronic pain of the left knee and left foot. Left foot painful and swollen (arrow), especially in back part and in region of Achilles. Problem in walking. The reason of the pathology: chronic distortion of left ankle joint and knee during getting off the car many times every day. On X-ray no changes. Clinically – instability of ankle joint and knee.

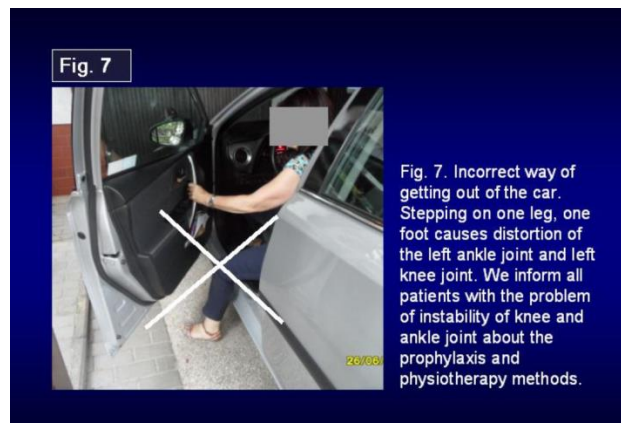
**Figure 6:** Patient in age of 65 y. Big and chronic pain of the left knee and left foot. Left foot painful and swollen (arrow), especially in back part and in region of Achilles. Problem in walking. The reason of the pathology: chronic distortion of left ankle joint and knee during getting off the car many times every day. On X-ray no changes. Clinically – instability of ankle joint and knee.

#### **Material. The group of patients with ankle insufficiency**

In 8 years, we have treated 32 patients (N = 32) suffering from chronic insufficiency due to the distortion of the ankle joint and leading to limitation of dorsal flexion of the foot and pain syndrome. The causes of “pain syndromes” were the distortion of the ankle or additionally in the knee appearing at the moment of getting out of the car. In right-hand traffic countries, in drivers (26 cases), this pathology is found in the left ankle, and in passengers (6 cases) in the right ankle. This illness is a new syndrome of foot pathology which has not been written - till our articles in the USA and the Czech Republic [14,21,24].

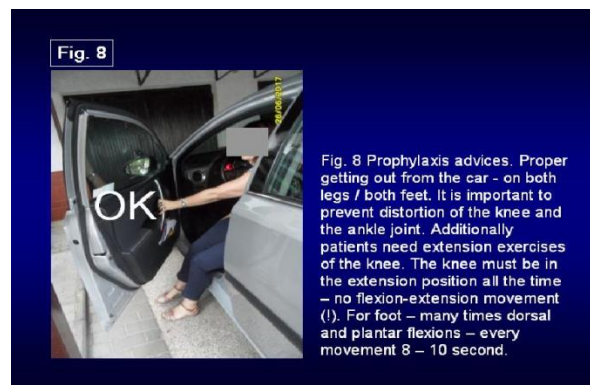
#### **Therapy and prophylaxis**

In the first place, patients must remove the causes of the problem - “rotation – distortion movement” of the ankle joint or knee joint [Figure 7,8]. It is essential to put both legs at the same time on the ground while getting out of the car. The exercises of dorsal flexion of the foot are important as well. Extension, and only extension, exercises for the knee are also very important. What is more, in all knee problems we advise only extension exercises, never flexion-to-extension exercises. Only isometric exercises of the m. quadriceps are proper. Exercises in warm water are extremely beneficial - best in geothermal water.



**Fig. 7.** Incorrect way of getting out of the car. Stepping on one leg, one foot causes distortion of the left ankle joint and left knee joint. We inform all patients with the problem of instability of knee and ankle joint about the prophylaxis and physiotherapy methods.

**Figure 7:** Incorrect way of getting out of the car. Stepping on one leg, one foot causes distortion of the left ankle joint and left knee joint. We inform all patients with the problem of instability of knee and ankle joint about the prophylaxis and physiotherapy methods.



**Fig. 8** Prophylaxis advices. Proper getting out from the car - on both legs / both feet. It is important to prevent distortion of the knee and the ankle joint. Additionally patients need extension exercises of the knee. The knee must be in the extension position all the time – no flexion-extension movement (!). For foot – many times dorsal and plantar flexions – every movement 8 – 10 second.

**Figure 8:** Prophylaxis advices. Proper getting out from the car - on both legs / both feet. It is important to prevent distortion of the knee and the ankle joint. Additionally patients need extension exercises of the knee. The knee must be in the extension position all the time - no flexion-extension movement (!). For foot - many times dorsal and plantar flexions - every movement 8-10 second.

## **DISCUSSION**

There are many different factors influencing insufficiencies of the feet or the knees associated with the pain. In our orthopedic practice, we could notice such problems in children and in adults:

1. Flat foot deformation in children and teenagers
2. Limited plantar flexion of the big toe and the other toes, usually among adults suffering from forefoot pain, detected by the flexion toe test [1,13,22,23],
3. Halluces valgi- very frequent among women [1,13,22-23],
4. Foot insufficiency among girls- Köhler disease,
5. Hereditary and neurogenic disorders of the foot in children and adults.
6. In adult knee varus deformity, with instability and pain syndromes.
7. In adult knee valgus deformity, with instability and pain syndromes.
8. Knee flexion's contractor - the limitation of extension even a 3-5 degree constitutes a problem and causes pain (!).
9. Recurvation of the knee- mostly both - in children and adults, as a symptom of Minimal Brain Dysfunction - very frequent [5,7,8,10-12,15,18,21].
10. "Pain Syndromes of Ankle Joint (PSofAJ) or / and Pain Syndrome of Knee Joint (PSofKJ) - are presented in the literature only in our articles published in the USA and in the Czech Republic [18,19,21]. In these articles we described such

syndrome among drivers using mostly small cars. The cause of pain syndromes is loosening of the ankle joint and / or the knee because of lengthening of synostosis tibio - fibulare and/or ligaments collaterale fibulare and mediale, ligaments of cruciatum of the knee.

## **CONCLUSION**

We described a new pathological syndrome of the ankle joint or / and knee joint connected with a chronic rotation-distortion movement during getting out of the car.

1. These abnormalities are affecting the left foot of the driver and the right foot of a passenger in right-hand traffic countries- like Poland, Germany, France.
2. Similar mechanisms can appear in physical work and in various daily activities, which provoke rotation of the trunk on the stabilized foot. Problems appear in the feet or / and the knees.
3. The symptoms of "Pain Syndromes of Ankle Joint or / and Pain Syndrome of Knee Joint are: instability of the ankle joint or / and knee joint, swelling, pain, limping, sometimes patients are unable to walk longer distances. Going up the stairs, climbing hills and mountains is especially difficult.
4. In the therapy we advise- proper way of getting off the car - both legs and both feet without any rotation movement of the trunk and proper kinesiotherapy, massage in water, laser, diadynamic, jonoforesis.

## **REFERENCES**

1. Arroyo-Hernández M, Mellado-Romero M, Páramo-Díaz P, et al. (2017) Chronic ankle instability: Arthroscopic anatomical repair. Spanish Journal of Orthopedic Surgery and Traumatology 61(2): 104-110.
2. Hurst B, Branthwaite H, Greenhalgh A, et al. (2017) Medical-grade footwear: the impact of fit and comfort. Journal of foot and ankle research 10(1): 2.
3. Karski T (1971) Usefulness of toe flexion test in the assessment of foot disability. Organ Surgery and Orthopedics Poland 36(6): 755.
4. [http://www.pojivo.cz/pu/LocomotorSystem\\_2017\\_01\\_170129.pdf#page=64](http://www.pojivo.cz/pu/LocomotorSystem_2017_01_170129.pdf#page=64)
5. Karski T (1980) Tests useful in assessing foot hazards"Biomechanics and prevention of static foot deformities.
6. Materials from the Scientific Session (1980) Materials from the scientific session. Lublin, PZWL 4-5(12): 113-116.

7. Karski T (1985) The toe flexion test for the recognition of early stages of functional disorders and deformities of the forefoot. *Contributions to Orthopedics and Traumatology* 32(6): 305.
8. Karski T (1990) Congenital and acquired foot defects in children; Orthopedics, traumatology and rehabilitation of motor organs, edited by Prof. St. Piątkowski, PZWL 217- 220.
9. Karski T, Konera W, Malicki M (1990) Static and jatrogenic knee plate deformities in children. Explanation of the phenomena and possibilities of therapy. Szekesfehervar, Orthopedic Congress in Hungary.
10. Orthopedic Days of the Hungarian Orthopedic Society.
11. Karski T (1990) Activities of the podiatric group in the Lublin orthopedic departments under the direction of Professor Stanisław Piątkowski. *Surgery of locomotor organs and Polish orthopedics* 3: 179-181.
12. Karski T, Karski J, Snela S, et al. (1995) Buckle foot deformities in children with spastic shortening of the Achilles tendon. *International Community Congress, Kurzfassungen-Block 6, Berlin*.
13. Karski J, T Karski, Snela S, et al. (1996) Foot damage in children with spastic shortening of the Achilles tendon. *Orthopädieschuhtechnik* 9/1996, Magazine for Prevention and Rehabilitation 24-26.
14. Karski T, Frelek KM, Papierkowski A, et al. (1996) Foot deformities with children with cerebral palsy Annual Meeting of the Hungarian Orthopedic Association.
15. Tomasz K, Jacek K (2015) Syndrome of contractures and deformities” According to Prof. Hans Mau as the primary cause of hip, neck, shank and spine deformities in Babies, youth and adults. *American Research Journal of Medicine and Surgery* 1(2).
16. Tomasz K, Jacek K (2015) Syndrome of Contractures and Deformities” According to Prof. Hans Mau as the Primary Cause of Hip, Neck, Shank and Spine Deformities in Babies, Youth and Adults. *American Research Journal of Medicine and Surgery* 1(2).
17. Karski J, Karski T, Pyrc J, et al. (2016) Deformations of the feet, knees, hips, pelvis in children and adults with minimal brain dysfunction Causes. *Treatment Prophylaxis Locomotor System*. 23: 1-134.
18. Karski J, Karski T, Karska K, et al. (2017) Ankle Joint Pathology of Car Drivers and Passengers. Case report. *American Research Journal of Medicine and Surgery* 2(1).
19. Karski T, Karski J (2017) Ankle joint, knee, Hip Distortion Syndrome connected with the using of small cars. *Crimson Publishers* 1(3): 1-4.
20. Karski T (2017) Physiotherapy - Correct, or incorrect, based on ‘wrong principles of treatment’. Example for Spine, Hip, Knee, Shank and Feet.1 (1): 1- 4.
21. Karski Tomasz, Karski Jacek, Pyrc Jaroslaw [2017]: Mozná príčina bolestiveho Syndromu kloubu dolni končetiny- popis a kasuistiky, A possible cause of the “Pain Syndrome of Lower Extremity Joints”. Description and Case Reports. *Locomotors System, Czech Republic* 24: 7(1)10.
22. Karski T, Jacek K, Klaudia K, et al. (2018) Pediatric Prophylaxis Program of Motor System Deformations and Illnesses in Children. *Problems of Spine, Hips, Knees and Feet, EC Paediatrics* 7(7): 704-714.
23. Karski T, Jacek K, Katarzyna K, et al. (2018) Prophylactic Rules for Newborns, Babies, Children and Adults in problems of Hip, Knee, Shank, Feet and Spine, *Crimson Publishers* (2)1: 110-112.
24. Menz HB (2016) Chronic foot pain in older people. *Maturitas* 91: 110 -114.
25. Vaillant J, Revillet P, Sevenier AM, et al. (2016) Impact of fatigue on postural control in quiet standing in fibromyalgia. *Annals of physical and rehabilitation medicine* 59: e124-e125.