

## Metaplastic Carcinoma of the Breast: A Case Study

Mohammad Al-Share<sup>1</sup>, Hanan Al-Asbahi<sup>1</sup>, Michleen Al-Awabdeh<sup>2</sup>, Maysaa Al-Khalailah<sup>3</sup>, and Mohammad Abu-Jeyyab<sup>4\*</sup>

<sup>1</sup>*AlBashir Hospital, Amman, Jordan*

<sup>2</sup>*Jordan University of Science and Technology, Amman, Jordan*

<sup>3</sup>*Balqa Applied University, Amman, Jordan*

<sup>4</sup>*Mutah University, Amman, Jordan*

Correspondence should be addressed to Mohammad Abu-Jeyyab, Mutah University, Amman, Jordan

Received: April 14, 2022; Accepted: May 05, 2022; Published: May 12, 2022

### **ABSTRACT**

Breast carcinosarcoma, metaplastic neoplasm of the breast, a rare type of breast tumors that accounts about 0.08 to 0.2 % of all breast cancers. carcinosarcoma is a mixed type of neoplastic cells. Carcino related to epithelial cells origin. Sarcoma is a mesenchymal cell malignant tumor. This is a sever bad prognosis cancer. A few cases were reported about breast carcinosarcoma, here in we have a case of 58 female patient that has a late stage of breast mass that was diagnosed as a breast carcinosarcoma. In this case report we will show the presentation of the patient, discuss the risk factors and put our treatment plan.

### **KEYWORDS**

Breast carcinosarcoma; Metaplastic neoplasm; Breast tumors; Neoplastic cells

### **INTRODUCTION**

Metaplastic carcinomas of the breast are heterogeneous neoplasms that contain both malignant epithelial and mesenchymal components. These tumors are thought to originate from malignant myofibroblasts or metaplastic differentiation of malignant epithelial cells within myofibroblasts. Clinically carcinosarcoma of the breast is an aggressive breast cancer. These tumors do not express the estrogen or progesterone receptors and HER-2/neu oncogene. Due to this "triple negative" phenotype, such tumors tend to be more aggressive [1].

Here we will discuss a case of a 60-years-old female patient that discovered a mass before a year and was diagnosed as a case of breast carcinosarcoma based on the history, the physical examination, radiological findings.

### **CASE PRESENTATION**

A 58-year-old female presented to the emergency room complaining of left breast ulcer associated with pus discharge. Prior to that, the patient was complaining of a painless lump at same breast which was ignored for one year, and there was no unexplained weight loss or bone pain. Then she was admitted and threatened as a case of breast abscess.

**Citation:** Mohammad Al-Share, Metaplastic Carcinoma of the Breast: A Case Study. Clin Surg J 5(2): 51-55.

Our patient was single and nulliparous. Menarche at age of 12 and menopause at age 46. She had a second-degree family history of breast cancer (diagnosed at age 30). The patient had no previous medical or surgical history, and no known allergies. She hadn't taken any hormonal therapy.

By the physical examination, a left breast fungating mass about 7 cm × 6 cm with overlaying redness and skin nodules, the mass was in the left upper quadrant and there was no tenderness. hard axillary lymphadenopathy.

### ***Radio-Imaging***

The Ultrasound of the left breast has shown a cystic lesion that was irregular, surrounded by a hypoechoic patch in the left upper quadrant. Flickers of calcification appear and extend to the left axilla. The left axilla had a septate cyst with a solid component and irregular borders measuring 3 cm × 3 cm.

The mammogram has shown a lobulated high density mass measuring (6 cm × 5 cm × 5.8 cm) in the upper outer quadrant of the left breast. Skin thickening, architectural distortion, intralesional microcalcifications, and surrounding coarsened trabeculations are also seen. The carcinoma appears as an obscured oval mass in the middle third of the inner?? Upper left breast.

### ***Enlarged Left Axillary Lymph Nodes***

A CT scan has shown a lobulated heterogeneous mass with central necrosis and draining sinus tract to the skin measuring (3.3 cm × 4.6 cm). Multiple enlarged necrotic lymph nodes are evident in the left axilla.

There are multiple ground glass opacities surrounding a nodule of soft tissue in the upper lobes, the largest of which measures 4.5 mm, and atelectatic bands in the lower lobes of both lungs.

Restaging Pan CT scan showed multiple bilateral sub centimeter in short axis deep cervical lymph nodes, bilateral sub centimeter supraclavicular lymph nodes enlargement, large left heterogenous lesion measuring (5.3 cm × 6.6 cm) in the upper outer quadrant of the left breast, with skin thickening.

A round hyperdense mass in the right breast measuring about 1 cm was noted. Large left axillary multiloculated with multiple septation surrounding enlarged lymph nodes.

Irregular radiotracer uptake is seen at the body of the sternum on bone scan. It was unremarkable otherwise

### ***Laboratory Findings***

All laboratory values of the patient were within the normal range except for a slight increase in basophils count

### ***Histopathology***

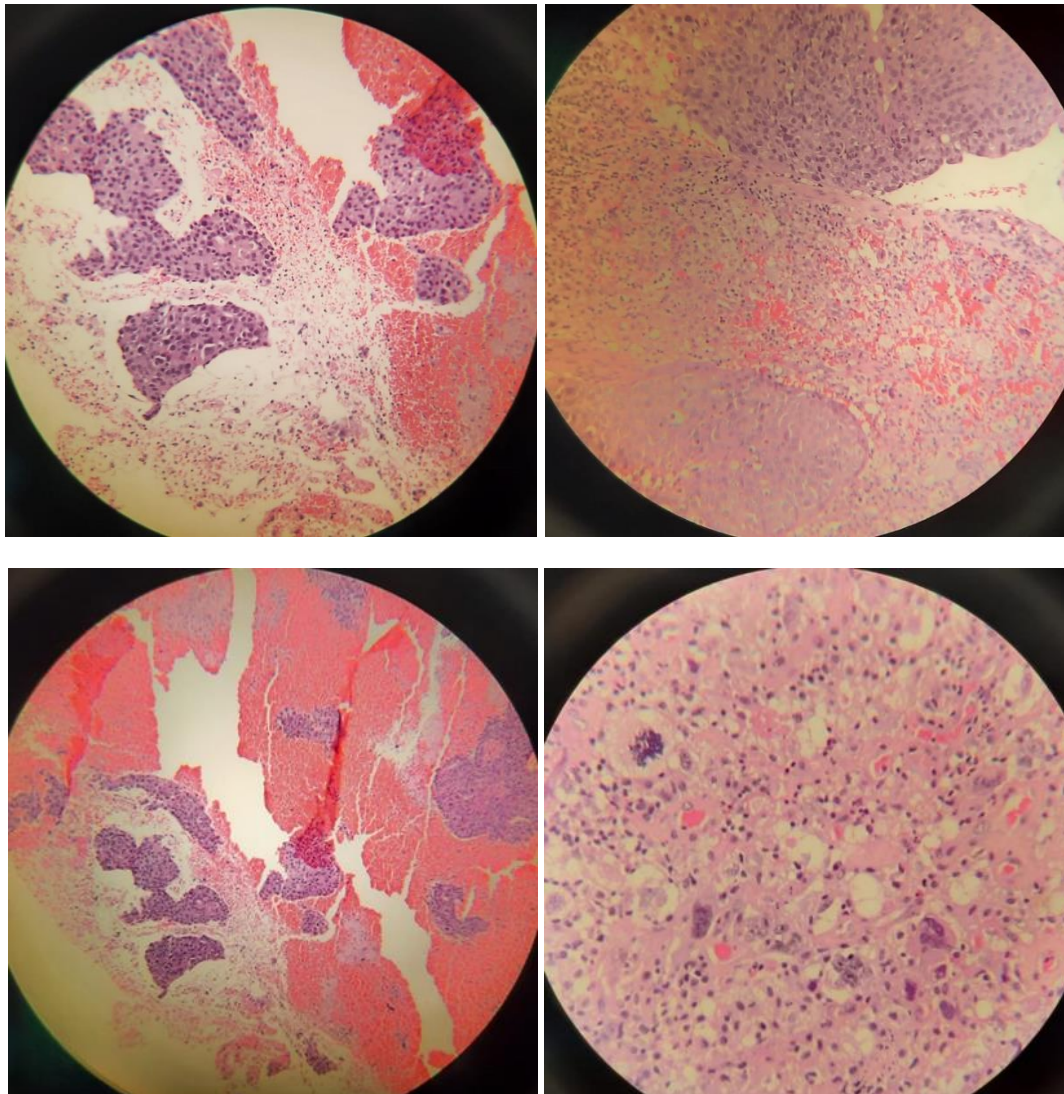
A biopsy of the mass was done; the histopathology shows poorly differentiated carcinosarcoma, the sarcoma component is pleomorphic undifferentiated, with chronic lymphocytic infiltration (Figure 1).

Grade 3/3 invasive mammary carcinoma ductal type.

Metaplastic carcinoma, high grade DCIS with comedonecrosis. ER, PR, HER2 all are negative.

### **DISCUSSION**

Carcinosarcomas are extremely rare biphasic malignant aggressive cancers. They have been observed in various human body organs including breast, ovary and uterus [1,2]. Carcinosarcomas of the breast are also known as metaplastic breast cancers (MBC) and account for 0.08%-0.2% of all breast malignancies. According to the SEER database less than 10,000 cases of MBC were reported annually in USA between 1973 and 2015 [3].



**Figure 1:** Histopathology of carcinosarcoma.

It is crucial to identify the clinical and pathological features of metaplastic breast cancer; in order to distinguish it from the other types of cancers specifically the uncommon ones. Histologically, these neoplasms have malignant epithelial and mesenchymal cellular components [1]. There is controversy regarding the origin of carcinosarcomas; as there are several theories which might provide interpretation for the origin of this type of breast cancer. Collision theory, combination theory and the conversion/metaplastic theory were introduced. Collision theory proposed that sarcomatous and carcinomatous cells develop from separate progenitor cells.

However, Monoclonal combination theory suggests that common multipotent precursor cells generate both sarcomatous and carcinomatous cells. On the other hand, the conversion/metaplastic theory conveys that the sarcomatous portion made out of carcinomatous particles via a metaplastic process. The latter is supported by reported data concluding that both epithelial and mesenchymal components of the tumor have cytokeratin, S-100, and vimentin positive expression of [3]. Not to mention, there are new studies suggest that MBC originates from single stem cells that develop into myoepithelial cells with biphasic differentiation [1], as

myoepithelial markers including CD10, p63, and actin are positive in this entity [3].

Based on Wargotz et al. study MBCs are divided into 5 groups (carcinosarcoma, matrix-producing carcinoma, spindle-cell carcinoma, squamous cell carcinoma and osteoclastic giant cell carcinoma) [4]. Another subtype categorization is also suggested by WHO; in that MBC are further classified as mixed metaplastic carcinoma, low-grade adenosquamous carcinoma, fibromatosis-like, squamous cell carcinoma, spindle cell carcinoma, and metaplastic carcinoma with mesenchymal differentiation [3].

Clinically, most of MBC diagnosed patients fall in to the range of above 50 years old in age. Based on a retrospective study conducted based on SEER database (from January, 1998 to December, 2016), the majority (81.2%) of patients with MBC were older than 50 years [4]. However, a median age of about 45.5 years was reported by a retrospective study done in Ankara hospital [5]. Patients ultimately present with well-defined, nodular, firm, concrete breast mass. Nevertheless, they may present with more benign-like clinical features such as well-defined circular-shaped regular lump which might be similar to the presentation of fibro-adenomas [2]. The initial course of disease seen in our patient was consistent with the benign-like features as the patient developed painless lump, then one year later she significantly developed skin changes; invasion, which was misdiagnosed as breast abscess at first. Core needle biopsy was performed to establish a proper diagnosis; as it revealed the presence of poorly differentiated carcinosarcoma with pleomorphic sarcomatoid component.

Breast cancer diagnosis is established by several means including clinical, radiological a histopathological modality. Ultrasonography, Mammography, magnetic resonance mammography is frequently employed as breast

imaging techniques. Yet, all these techniques are suboptimal when it comes to diagnosing breast carcinosarcoma. Besides pre-surgical diagnosis of breast neoplasms can be obtained by commonly used bed-side procedures including fine needle biopsy and or core biopsy. However, preoperative diagnosis can be challenging [6]. diagnosis of breast lumps by frozen section is accurate, with a sensitivity and specificity percentage of more than 90 and 99%, respectively [6]. Conversely, in breast MBC, there may be some limitations to frozen section diagnosis. Unfortunately, our patient has to have neoadjuvant therapy prior to surgical intervention. As a result, there was no frozen section taken.

On histopathological and hormonal survey's, this type of cancer is typically considered a triple-negative breast cancer (TNBC). In other words, it lacks the expression of estrogen receptor (ER), progesterone receptor (PR), and human epidermal growth factor 2 receptor (HER2) [3]. This is applicable in our case as it has negative response to receptors (TNBC). On the other hand, there is an essential need to have more understanding for MCB.

Moreover, metaplastic carcinoma of the breast has poor prognosis compared to non-metaplastic triple negative breast carcinomas. Though MBC has similar clinical presentation to invasive ductal carcinoma [1]; carcinosarcomas present with large tumors, high histological grade, heterogeneity, overexpression of p53 and Ki-67, as well as less lymphatic invasion as spread of this disease occurs mostly through blood vessels; hematological dissemination [3,7]. As a result, it is far more aggressive than invasive ductal carcinoma, even when matched for age, stage, and tumor grade [3]. In which patients with MBC already have advanced disease at time of diagnosis with metastases most commonly to pleura and lungs then metastases to bone and liver are followed [2,7].

In comparison to triple negative breast cancer whether lobular or ductal types, carcinosarcomas present with more advanced disease on local basis. MBC follows the same treatment guidelines of TNBC because there is no standard protocol for the treatment of such rare cancer type [1]. Surgery could be an option of treatment as seen in some reported case of young age [6]. Poor response to systemic chemotherapy; more chemo refractory than TNBC along with unsatisfactory response to neoadjuvant

therapy [3], with poor clinical aftereffect has been observed [2]. Additionally, these patients have higher risk of recurrence, and a short disease-free period as well as less overall survival time [3].

Finally, New studies are being conducted to obtain better perception and understanding of the prognosis, morphology and course of treatment of this tumor [3].

### **REFERENCES**

1. Esses KM, Hagmaier RM, Blanchard SA, et al. (2009) Carcinosarcoma of the breast: two case reports and review of the literature. *Cases Journal* 2(1): 15.
2. Kanaizumi H, Higashi C, Tanaka Y, et al. (2019) Carcinosarcoma of the breast: A case of breast conservation surgery and breast reconstruction. *SAGE Open Medical Case Reports* 4(7): 2050313X19853684.
3. Reddy TP, Rosato RR, Li X, et al. (2020) A comprehensive overview of metaplastic breast cancer: Clinical features and molecular aberrations. *Breast Cancer Res* 22: 121.
4. Cai W, Zhuang Y, Chen J, et al. (2021) Effect of postmastectomy radiotherapy on survival outcomes of patients with metaplastic breast cancer. *Nan Fang Yi Ke Da Xue Xue Bao: Journal of Southern Medical University* 41(11): 1733-1740.
5. Esbah O, Turkoz FP, Turker I, et al. (2012) Metaplastic breast carcinoma: Case series and review of the literature. *Asian Pacific Journal of Cancer Prevention* 13(9): 4645-4649.
6. Tian W, Xu D (2012) Diagnosis and management of multiple carcinosarcoma of the breast in a young Chinese patient. *Breast Care (Basel)* 7(2): 147-149.
7. Kennedy WR, Gabani P, Acharya S, et al. (2019) Clinical outcomes and patterns of care in the treatment of carcinosarcoma of the breast. *Cancer Medicine* 8(4): 1379-1388.