

Management and Treatment of Wounds by Projectile from a Firearm in Hand in the Plastic and Reconstructive Surgery Service of the Central Military Hospital in Two Years

Brenda Arcos Vera*, Felipe Alejandro López Silva and Héctor Adolfo Morales Yépez

Plastic and Reconstructive Surgery Service of Hospital Central Militar Hospital, Mexico

Correspondence should be addressed to Brenda Arcos Vera, perladeshicon@hotmail.com

Received: June 19, 2021; Accepted: July 5, 2021; Published Date: July 12, 2021

ABSTRACT

INTRODUCTION

Gunshot wounds are a major cause of morbidity and lead to serious socioeconomic problems. Wounds often causing severe functional sequelae. Therefore, it is vitally important to provide proper management of these wounds.

OBJECTIVES

Define the treatment of gunshot wounds at the Central Military Hospital in the period from March 2019 to March 2021.

MATERIAL AND METHODS

It is a descriptive, retrospective, observational study.

RESULTS

Patients who fulfilled the diagnosis presented 3 metacarpal fractures (27.27%), 2 metacarpal and phalangeal fractures (18.18%), 2 fractures of phalanges (18.18%), 1 carpal + metacarpal fractures (9.09%), 3 with injury only to skin cell tissue without evidence of fractures (27.27%). Therapeutic management: 3 patients received external fixator, 2 ORIF, 1 external fixator + ORIF + inguinal flap + bone graft, 1 external fixator + bone graft + ORIF, 0 wound closure, 4 management with wet therapy.

CONCLUSIONS

The wounds by firearm in hand are frequent injuries, which merit immediate treatment. This depends on the complexity of the injury for a speedy recovery and integration into the workplace.

KEYWORDS

Gunshot wounds

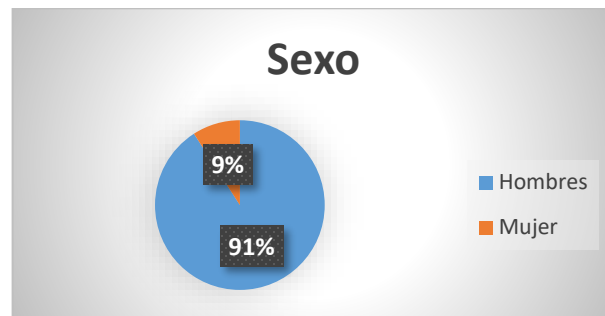
Citation: Brenda Arcos Vera, Management and Treatment of Wounds by Projectile from a Firearm in Hand in the Plastic and Reconstructive Surgery Service of the Central Military Hospital in Two Years. Clin Surg J 4(S11): 15-19.

INTRODUCTION

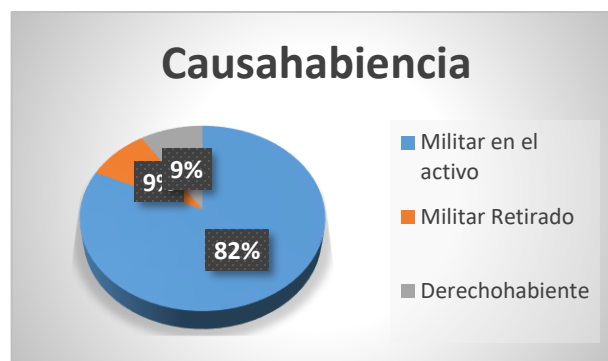
To date, gunshot wounds (HPAF) constitute a public health problem in the world. This fact is influenced by multiple factors such as family disintegration, unemployment, early incorporation into criminal groups, experiences with drugs, uncontrolled dissemination of violent acts through the mass media, as well as greater ease in acquiring weapons [1]. In Each year in the United States, 30,000 to 50,000 people die secondary to HPAF, and they constitute the first cause of death in the first two decades of life; Furthermore, it is estimated that for each death there are at least thew disabling injuries. With regard to homicide, it mainly affects men; the most affected age range being 15 years to 34 years [1,2].

In Mexico, it is evident that the frequency of these injuries has increased [2]. In the last 15 years, injuries from this type of projectile have increased significantly; causing damage through tissue disruption, hemorrhage and infectious processes. These types of wounds are often contaminated with foreign materials such as cloth, dirt, stones, bullets, and splinters [3]. It is therefore important to promptly manage these injuries.

The Central Military Hospital receives both civilian patients who suffer assaults on public roads and active military patients who suffer assaults due to assaults and during confrontations against armed groups [2]. Due to the use of means of protection in the thorax and head, the extremities are areas vulnerable to projectiles and explosions. These are affected with a frequency of 60-80%, and the hand in particular in about 25%, for being these infrequent sites. The injuries are generally caused by low-speed missiles (pistols), tending to cause complex injuries to the upper extremities [4-6], causing prolonged or permanent disabilities with a personal, social and economic impact on young adults and different degrees of severity [7-9] (Graph 1 - Graph 4).



Graph 1: Distribution by sex.



Graph 2: Distribution by probate.

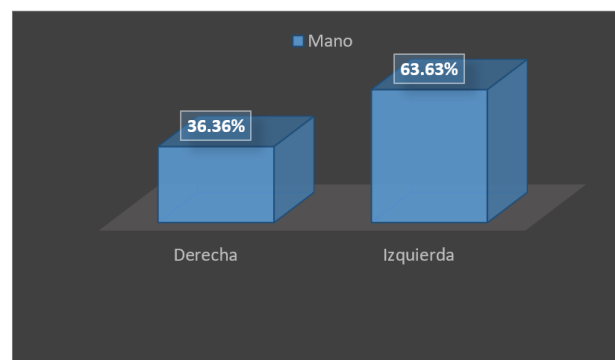
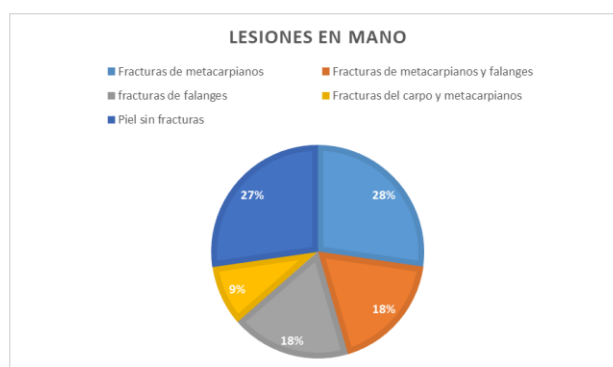
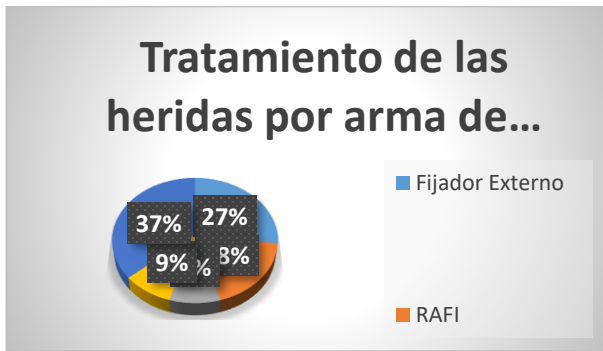


Table 1: Injured hand.



Graph 3: Hand injuries due to projectile wounds from a firearm.



Graph 4: Treatment of gunshot wounds from a firearm. Ballistics.

In firearms injuries, three components can be distinguished: entry port, trajectory, and exit site [10] (Figure 1 - Figure 8).

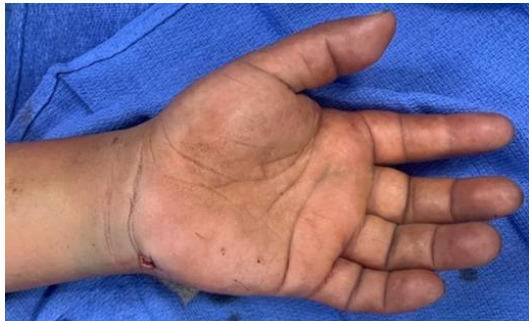

Figure 1: 8 mm x 6 mm firearm projectile wound entry hole in the left hand in flexor zone IV.

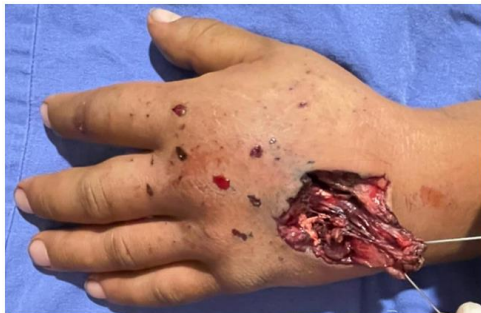

Figure 2: Outlet path with lesion in left hand extensor zone VI causing skin defect of 4 cm x 3 cm.

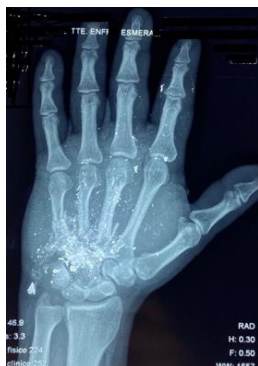

Figure 3: Multifragmented fractures of the base of the 3rd, 4th, 5th metacarpals, large, hamate, pisiform of the left hand.

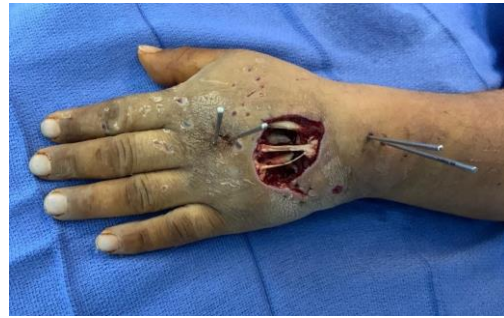

Figure 4: Lesion of 50% of the extensor tendon of the 3rd, 4th and 5th fingers, extensor of the 2nd integral finger of the left hand.

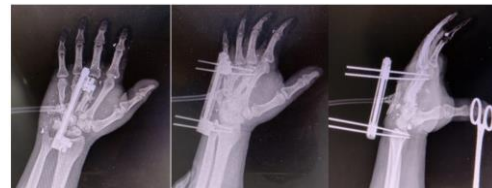

Figure 5: AP, oblique and lateral X-ray control of the 9.5 cm external fixator in the head of the 3rd metacarpal to the distal radius of the left hand.

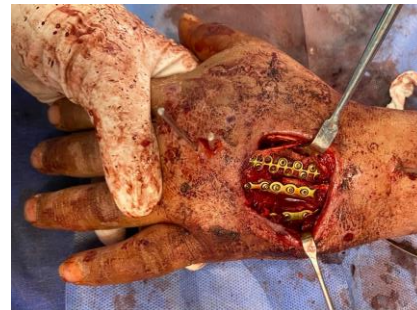

Figure 6: Reconstruction of the left hand with reduction of fractures with bone graft of the left iliac crest (measures 11 cm, for bone defects of the 3rd, 4th and 5th metacarpal of 7 cm, 5cm and 4 cm) as well as 4 titanium plates system 2.0 1) 16-hole double to 3rd metacarpal 2) 9-hole T-plate. 3) Simple plate with 4 holes towards 4th metacarpal and 4) with 6 holes towards 5th metacarpal.

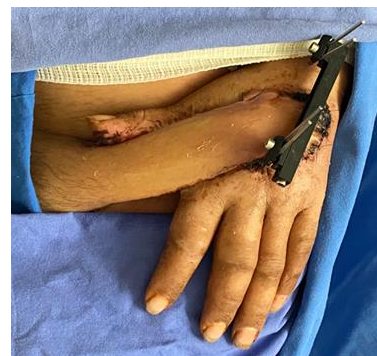

Figure 7: Coverage of the skin defect with a left inguinal fasciocutaneous flap.

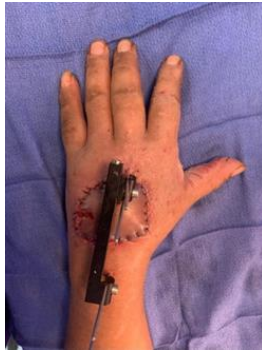

Figure 8: Inguinal flap release.

ENTRY ORIFICE

Corresponds to a smaller contused wound; Among its characteristics are the carbonaceous halo (false tattoo or smoking) which corresponds fundamentally to the deposit of the elements of deflagration of the gunpowder around the entrance orifice. The flash from the muzzle will cause a burn, so a period of observation is required. If it is an area where the skin is on a bone plane, the following characteristics may be present: Hoffman lesion, stellate lesion, Benassi sign and impression of the cannon on the skin. The "quarter mine" or Hoffman lesion corresponds to a pocket between the skin and the bone; produced by the sudden expansion of the jet of compressed gas after the shot.

INTRACORPORAL TRAJECTORY

During its intracorporeal trajectory, the projectile releases kinetic energy towards the surrounding tissues perpendicular to its trajectory, generating a shock wave that, due to their elasticity, produces a space called "temporary cavity"; but if the shock wave exceeds the resistance of the tissues, they rupture, generating a

definitive cavity greater than the diameter of the projectile. If an easily accessible projectile is found, it must be removed.

UTLET HOLE

It is formed by the pressure exerted by the projectile from the inside out, everting the skin, the exit orifice tends to be larger and more irregular than the entrance orifice, giving the appearance of having exploded outwards due to the energy they release [8,10].

In the context of wound ballistics, these have 2 classifications, the 1st one classifies it as Low velocity <2500 ft/s (750 m/s) and high velocity = or >2500 ft [2] The 2nd classification is divided into: Low velocity <350 m/s (pistols), intermediate 350 m/s - 600 m/s (shotguns), high velocity 600 m/s - 700 m/s (rifles, 357 revolver, automatic and semi-automatic weapons) causing "explosive effects" [8,9].

Injuries caused by HPAF present multiple variables in terms of their production or ballistics mechanism, the site of the injury, the anatomical regions affected, the degrees of injury produced and the evolution that the affected organs may have. The amount of kinetic energy transferred from the projectile to surrounding tissues, internal organs and directly damaged structures, as well as the final location of the projectile, determines the severity of gunshot projectile wounds [1]. These injuries are complex due to their proximity neurovascular structures and the concurrent participation of various tissues (tendinous, bone or nerve) [3]; which require complex and meticulously planned treatments.

REFERENCES

1. Canseco Cavazos JC, Palacios Zertuche J, Reyna Zepúlveda F, et al. (2017) Epidemiology of firearm projectile injuries at the "Dr. José Eleuterio González" from the Autonomous University of Nuevo León. *Surgery and Surgeons* 85(1): 41-48.
2. García Valadez LR, Hernández Téllez IE, Castellanos Velazco CA, et al. (2015) Epidemiology of wounds due to firearm projectile in the Central Military Hospital of Mexico. *Revista de Sanidad Militar* 69: 204-217.

3. Sari A, Ozcelik IB and Bayirli D, et al. (2020) Management of upper extremity war injuries in the subacute period: A review of 62 cases. *International Journal of the Care of the Injured* 51(11): 2601-2611.
4. Betancourt GS, Croas FA (2010) Treatment of traumatic hand injuries caused by firearms. *Cuban Journal of Orthopedics and Traumatology* 24(2): 70-80.
5. Pereira C, Boyd B, Olsavshi A, et al. (2012) Outcomes of complex gunshot wounds to the hand and wrist. A 10-year level i urban trauma center experience. *Annals of Plastic Surgery* 68 (4): 374- 377
6. De la Rosa-Massieu D, González-Sánchez M, Onishi-Sadud W, et al. (2014) Severe hand injury from a high-energy firearm projectile with carpal arthrodesis and synthetic bone graft plus external fixators. Report of a case. *Mexican Orthopedic Act* 28(4): 240-243.
7. García G, Deichler F, Torres E (2011) Firearms injuries from a medical-criminalistic perspective. *Chilean Journal of Surgery* 63(3): 327-331.
8. Magaña Sánchez IJ, Torres Salazar JJ, García Núñez LM, et al. (2011) Basic concepts of ballistics for the surgeon general and its application in the evaluation of abdominal trauma. *General Surgeon* 33 (1): 48-53.
9. Stefanopoulos PK, Hadjigeorgiou GF, Filippakis K, et al. (2014) Gunshot wounds: A review of ballistics related to penetrating trauma. *Journal of Acute Disease* 3(3): 178-185.
10. Bhandari PS, Maurya S, Mukherjee MK (2012) Reconstructive challenges in war wounds. *Indian Journal of Plastic Surgery* 45(2): 332-339.