

Imaging Pelvic Congestion Syndrome

Lokesh Rana^{1*}, Ram krishan Abrol², Nishant Nayyar¹, Sudhir Yadav¹, Inderjeet Chauhan¹, Kirti Kumar Sharma¹ and Smit Rangani¹

¹Department of Radio-diagnosis, Dr. Rajendra Prasad Government Medical College, India

²Department of Surgery, Dr. Rajendra Prasad Government Medical College, India

Correspondence should be addressed to Lokesh Rana, poojalokesh2007@gmail.com

Received: January 07, 2020; Accepted: January 22, 2020; Published: January 28, 2020

ABSTRACT

Pelvic congestion syndrome is a common condition frequently ignored by radiologists, and it can be severely painful and debilitating in women and is potentially treatable with ovarian vein embolization [1,2]. It results from retrograde flow through incompetent valves in the ovarian veins. We present a case of pelvic congestion syndrome in a young female with characteristic computed tomographic appearance [2].

KEYWORDS

Congestion; Veins

1. CASE REPORT

We present a case of old female lady. A 22 year female presenting with chronic non-cyclical pelvic pain with increased frequency of urine. The CECT images shows multiple tortuous para-uterine dilated veins with diameter

>4 mm. Ovarian veins were also dilated bilaterally. There is also presence of asymmetrical circumferential thickening of urinary bladder. Diagnosis of chronic pelvic congestion and cystitis were made (Figure 1)

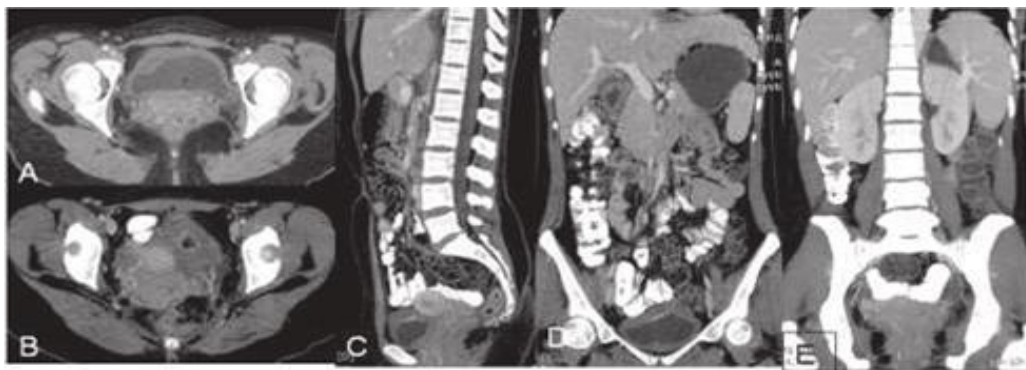


Figure 1: A chronic non-cyclical pelvic pain CECT images shows multiple tortuous para-uterine dilated veins with diameter > 4mm.

Citation: Lokesh Rana, Imaging Pelvic Congestion Syndrome. J Clin Cases Rep 4(2): 28-29.

2582-0435/© 2021 The Authors. Published by TRIDHA Scholars.

DISCUSSION

The diagnosis of pelvic congestion syndrome (PCS) continues to challenge all physicians' especially general surgery, obstetrics and gynecology. It tends to be more common in multiparous, premenopausal women who typically present with chronic pelvic pain for more than 6 months [1,3]. Approximately 10% of the general female population may have pelvic varices, and 60% of those women may develop this syndrome. It is a common condition frequently ignored by radiologists, and it can be severely painful and debilitating in women and is potentially treatable with ovarian vein embolization [1]. It results from retrograde flow through incompetent valves in the ovarian veins [2].

3. CLINICAL PRESENTATION

Female patients presenting with chronic pelvic pain which is non-cyclical in nature [1].

3.1 Key imaging diagnostic clues

1. USG-Multiple dilated tortuous para-uterine veins with diameter >4 mm and decreased PSV upto 3 cm/cm seen better with valsalva manoeuvre [2,4].
2. CT showing dilated veins in pelvic veins >4 mm and ovarian veins >8 mm [2,5].
3. MRI in addition to the above mentioned CT findings multiple flow voids seen in pelvis on T2W and T1W images and gradient images showing high signals within the tortuous veins [5,6].

4. CONCLUSION

Pelvic congestion syndrome is a common condition frequently ignored by radiologists, and it can be severely painful and debilitating in women and is potentially treatable with ovarian vein embolisation. Purpose of presenting this case to bring to the notice of the readers the diagnostic clues in this common and commonly ignored treatable condition.

REFERENCES

1. Knuttinen MG, Xie K, Jani A, et al. (2015) Pelvic venous insufficiency: Imaging diagnosis, treatment approaches, and therapeutic issues. *American Journal of Roentgenology* 204(2): 448-458.
2. Park SJ, Lim JW, Ko YT, et al. (2004) Diagnosis of pelvic congestion syndrome using transabdominal and transvaginal sonography. *American Journal of Roentgenology* 182(3): 683-688.
3. Rozenblit AM, Ricci ZJ, Tuvia J, et al. (2001) Incompetent and dilated ovarian veins: A common CT finding in asymptomatic parous women. *American Journal of Roentgenology* 176(1): 119-122.
4. Ascitutto G, Mumme A, Marpe B, et al. (2008) MR venography in the detection of pelvic venous congestion. *European Journal of Vascular and Endovascular Surgery* 36(4): 491-496.
5. Kauppila A (1970) Uterine phlebography with venous compression: A clinical and roentgenological study. *Acta Obstetrica et Gynecologica Scandinavica* 49(Suppl. 3): 1-66.
6. Yang DM, Kim HC, Nam DH, et al. (2012) Time-resolved MR angiography for detecting and grading ovarian venous reflux: Comparison with conventional venography. *The British Journal of Radiology* 85(1014): e117-e122.