Clinical Surgery Journal

Case Report | Vol 4 Iss S10

Dentigerous Cyst with Horizontal Impaction of Third Molar: A Case Report

Sheryl Ann Sajan, Anita Verghese, Shilpa L, Bhargabi Majumdar, Rithul P, Preethi A Poonja, Prasanna Kumar Rao*, and Raghavendra Kini

Department of Oral Medicine & Radiology, AJ Institute of Dental Sciences, Kuntikana, Mangaluru 575004, Karnataka, India

Correspondence should be addressed to Sheryl Ann Sajan, drjpkrao@gmail.com

Received: January 18, 2021; Accepted: January 30, 2021; Published Date: February 22, 2021

ABSTRACT

Dentigerous cyst is an epithelial- lined, developmental cyst that is benign in nature. It is formed due to fluid accumulation between the altered reduced enamel epithelium and the tooth Crown at the cemento-enamel junction of an unerupted tooth. It is the second most common cyst of the oral cavity after radicular cyst. It accounts for 22.3% of all true cysts in the jaws. They are most seen in unerupted third mandibular molars (65% common), maxillary canines, maxillary third molars and mandibular second premolars. Here, we present a case of a dentigerous cyst in a 22-years old male patient associated with an impacted mandibular right third molar.

KEYWORDS

Dentigerous; Benign; Reduced enamel epithelium; Cemento-enamel junction; Impacted

INTRODUCTION

Dentigerous cyst is defined as a 'cyst that originates by the separation of the follicle from around the crown of an unerupted tooth.' The term was coined by Paget in 1853 [1]. They are usually solitary in occurrence and are seen commonly in the first to third decades of life with a more male predilection. About 70% of the dentigerous cysts occur in the mandible and 30% in maxilla [2]. Small dentigerous cysts are usually asymptomatic and found incidental on radiographic examination [3]. Whereas larger cysts cause painless expansion of bone in the involved area with facial asymmetry.

CASE REPORT

A 22-years old, medically fit, male patient reported to our dental outpatient department with the complaint of pain in the right lower back teeth region for one week. The Pain was gradual in onset, continuous and insidious in nature. Initially the pain was dull aching which was later sharp and aching in nature. There were no aggravating and relieving factors. The Patient gives history of taking medications (analgesics) for relieving the pain, but it made no difference. The patient gives a history of smoking 4 times a day for past 2 years.

On extra-oral examination, facial asymmetry with diffuse swelling on the right side of the face involving the angle of the mandible was present (Figure 1). Solitary, mobile, submandibular lymph node, firm in consistency was palpable with tenderness. On intra-oral examination, there was reduced mouth opening with the third molars missing from all four quadrants (Figure 2). There was a diffuse swelling present involving the area of mandibular right

Citation: Sheryl Ann Sajan, Dentigerous Cyst with Horizontal Impaction of Third Molar: A Case Report. Clin Surg J 4(S10): 41-45.

third molar region extending from mandibular right first molar region to the retromolar area. Which was firm and tender on palpation. On inspection inflamed, pericoronal flap was present with buccal and lingual vestibules enlarged with no mucosal discoloration. Vestibular tenderness and obliteration were present on palpation.

Figure 1A and Figure 1B: Facial asymmetry with diffuse swelling present on the right side of the face involving the angle of the mandible.

Figure 2: Reduced mouth opening seen.

Figure 3: Panoramic radiograph showing ill-defined radiolucency with sclerotic borders involving the mandibular third molar region extending from mandibular right first molar to the ramus region.

Standardization in Training and Practice

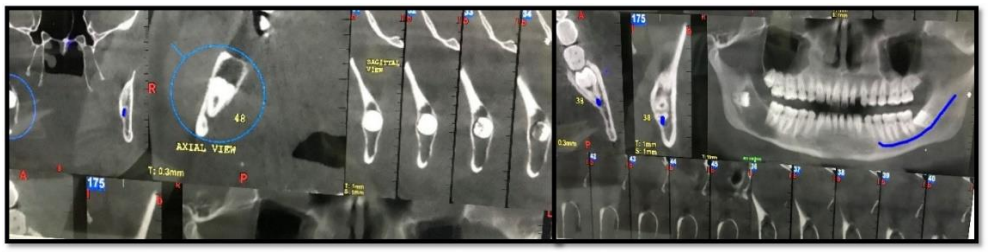

Figure 4: Cone beam tomography sections reveal a radiolucency in the region of mandibular third molar.

Advised orthopantomograph which revealed a unilocular, well-defined radiolucency with fully formed, ectopic impacted third molar in the right ramus region (Figure 3). The cyst lining was extending from the middle of the ramus distal to mandibular right first molar region. Cone-beam computed tomography sections confirmed the panoramic reports (Figure 4). Incisional biopsy was performed which confirmed dentigerous cyst.

DISCUSSION

Dentigerous cysts are most common developmental cyst of odontogenic origin [4]. It is attached to the cemento-enamel junction of the tooth cervix and encloses the crown on an unerupted tooth [4]. It is most prevalent, comprising 14% to 24% of the entire jaw cyst [5,6].

They are found more in common in association with any unerupted tooth, most often they involve mandibular third molars. Other sites include maxillary canines, maxillary third molars and mandibular second premolars ranked in their frequency [7].

Ectopic teeth are those located in the jawbones, mandibular condyle, followed by ramus, coronoid process, the sigmoid notch and the angulus in terms of frequency [8,9]. Ectopic eruption occurs as a result of 1 of 3 distinct processes that is disturbance in tooth development during odontogenesis, pathological process such as cysts and iatrogenic activity or else it is idiopathic [10-15].

In our case, the cyst was seen to involve interrupted right mandibular third molar ectopically present in the ramus region. The eruption and expansion of the cyst occupying a large space in the ramus might have directed the molar in an altered position.

Dentigerous cyst is more commonly seen in patients of second and third decades and rarely seen in infants [1]. It is also slightly common in males than females [2]. Whites are more affected than blacks [16]. If the cyst is small then the symptoms are usually asymptomatic, but once affected the patient represents symptoms of pain, paresthesia and swelling. These symptoms are usually present due to the adjacent tissues affected. The diagnosis of ectopic third molar cysts is done based on panoramic view or cone beam computed tomography imaging. Dentigerous cysts are usually seen solitary, slow growing, asymptomatic that are incidentally found during routine radiographs [7]. Based on the clinical symptoms present, the patient gave history of pain, swelling and trismus.

Radiographically, they appear unilocular, radiolucent area associated with the crown of an unerupted tooth. It is usually well-defined with corticated border but if infected may show ill-defined borders [7]. A large cyst may give the impression of a multilocular appearance because of the presence of bony trabeculae within the radiolucency. Depending on the cyst-to-crown ratio there are different varieties present. [1] central variety (which is the most common type, where the cysts surround the Crown of the tooth), [2] lateral variety (usually associated with the mesioangular impacted mandibular 3rd molar that is

partially erupted), [3] circumferential variant (the cyst surrounds the Crown and extends for some distance along the route so that a significant portion of the root appears to lie within the cyst) [7,17]. Fourth variety involves rarely a third molar displaced into the lower border of the mandible or higher up into the ascending ramus. The last variety includes maxillary anterior teeth displaced into the floor of the nose and other maxillary teeth moved through the maxillary sinus to the floor of the orbit.

In this case, radiographically, lesion was seen involving the ramus of a mesioangular impacted mandibular right third molar region with sclerotic borders with a lateral variety. CBCT imaging gives a clear and accurate 3-dimensional information regarding the exact position of the tooth and the surrounding structures.

Dentigerous cysts are treated by enucleation [17], marsupialisation [18] or decompression of the cyst by fenestration [7]. The major disadvantage of marsupialisation is recurrence or persistence of the lesion [1]. Motamedi et al. suggested the criteria for selecting the treatment modality based on the age, size, location, stage of root development, position of the involved tooth and relation of the lesion to the adjacent tooth and vital structure. When the cysts are large such as in our case, enucleation of the cyst with extraction of the cyst associated unerupted tooth is preferred [17]. Prognosis is excellent for most dentigerous cysts and recurrence is seldom noted. As the lining has a pluripotent capacity, these lesions may progress to form ameloblastoma, mucoepidermoid carcinoma and squamous cell carcinoma [16,19,20].

CONCLUSION

In this case report, dentigerous cyst associated with an unerupted mandibular third molar displaced in the ramus region is highlighted [21]. They are asymptomatic and undiscovered unless they cause symptoms which in this case was presented with pain, swelling, reduced mouth opening. Exact treatment can be devised only after proper investigations done such as orthopantomography, cone beam computed tomography and biopsy. Surgical approach must be carefully planned, choosing the more conservative and safer technique [22-28].

REFERENCES

1. Kasat VO, Karjodkar FR, Laddha RS (2012) Dentigerous cyst associated with an ectopic third molar in the maxillary sinus: A case report and review of literature. Contemporary Clinical Dentistry 3(3): 373.
2. Bhaskar SN(1986) Synopsis of oral pathology. 7th (Edn.), CBS Publisher; New Delhi: 228-37.
3. Scholl RJ, Kellett HM, Neumann DP, et al. (1999) Cysts and cystic lesions of the mandible: Clinical and radiologic-histopathologic review. Radiographics 19(5): 1107-1124.
4. Celebi N, Canakci GY, Sakin C, et al. (2015) Combined orthodontic and surgical therapy for a deeply impacted third molar related with a dentigerous cyst. Journal of Maxillofacial and Oral Surgery 14(1): 93-95.
5. Regezi AJ, Sciubba JJ (1999) Cysts of the oral region in oral pathology: Clinical pathologic correlations. 3rd (Edn.), Philadelphia: 288-321.
6. Rubin D, Vedrenne D, Portnof J (2003) Orthodontically guided eruption of mandibular second premolar following enucleation of an inflammatory cyst: A case report. Journal of Clinical Pediatric Dentistry 27(1): 19-23.
7. Mishra R, Tripathi AM, Rathore M (2014) Dentigerous cyst associated with horizontally impacted mandibular second premolar. International Journal of Clinical Pediatric Dentistry 7(1): 54.
8. Boutros E, Sabe-Alarab M, Jaber F, et al. (2017) Ectopic third molar in the mandibular jaw: Literature 3: 45-47.

9. Iglesias-Martin F, Infante-Cossio P, Torres-Carranza E, et al. (2012) Ectopic third molar in the mandibular condyle: A review of the literature. Oral Medicine Oral Pathology and Oral Surgery 17(6): e1013.
10. Wu Y, Song Y, Huang R, et al. (2017) Comprehensive analysis of ectopic mandibular third molar: A rare clinical entity revisited. Head & Face Medicine 13(1): 1-9.
11. Fındık Y, Baykul T (2015) Ectopic third molar in the mandibular sigmoid notch: Report of a case and literature review. Journal of Clinical and Experimental Dentistry 7(1): e133.
12. Buyukkurt MC, Omezli MM, Miloglu O (2010) Dentigerous cyst associated with an ectopic tooth in the maxillary sinus: A report of 3 cases and review of the literature. Oral Surgery, Oral Medicine, Oral Pathology, Oral Radiology, and Endodontology 109(1): 67-71.
13. Keros J, Sušič M (1997) Heterotopia of the mandibular third molar: A case report. Quintessence International 28(11).
14. Prasad TS, Sujatha G, Niazi TM, et al. (2007) Dentigerous cyst associated with an ectopic third molar in the maxillary sinus: A rare entity. Indian Journal of Dental Research 18(3): 141.
15. Wang CC, Kok SH, Hou LT, et al. (2008) Ectopic mandibular third molar in the ramus region: Report of a case and literature review. Oral Surgery, Oral Medicine, Oral Pathology, Oral Radiology, and Endodontology 105(2): 155-161.
16. Mahajan S, Raj V, Boaz K, et al. (2006) Non-syndromic bilateral dentigerous cysts of mandibular premolars: A rare case and review of literature. Hong Kong Dental Journal 3(2): 129-133.
17. Valdes Reyes JM, Espinoza Bermudez JA, Ghannam Ruisánchez YE (2016) Dentigerous cysts. Case Report Journal of Advanced Oral Research 7(1).
18. Asnani S, Mahindra U, Rudagi BM, et al. (2012) Dentigerous cyst with an impacted third molar obliterating complete maxillary sinus. Indian Journal of Dental Research 23(6): 833.
19. Slootweg PJ (1987) Carcinoma arising from reduced enamel epithelium. Journal of Oral Pathology & Medicine 16(10): 479-482.
20. Yasuoka T, Yonemoto K, Kato Y, et al. (2000) Squamous cell carcinoma arising in a dentigerous cyst. Journal of Oral and Maxillofacial Surgery 58(8): 900-905.
21. Meningaud JP, Oprean N, Pitak-Arnnop P, et al. (2006) Odontogenic cysts: A clinical study of 695 cases. Journal of Oral Science 48(2): 59-62.
22. Goutzanis L, Chatzichalepli C, Avgoustidis D, et al. (2020) Extraoral surgical removal of an ectopic impacted third molar of the mandible. Report of a case. Journal of Clinical and Experimental Dentistry 12(6): e615.
23. Lee JH, Kim SM, Kim HJ, et al. (2014) Characteristics of bony changes and tooth displacement in the mandibular cystic lesion involving the impacted third molar. Journal of the Korean Association of Oral and Maxillofacial Surgeons 40(5): 225.
24. Martinelli-Kläy CP, Martinelli CR, Martinelli C, et al. (2019) Unusual imaging features of dentigerous cyst: A case report. Dentistry Journal 7(3): 76.
25. Riachi F, Khairallah CM, Ghosn N, et al. (2019) Cyst volume changes measured with a 3D reconstruction after decompression of a mandibular dentigerous cyst with an impacted third molar. Clinics and Practice 9(1): 12-17.
26. Wu Y, Song Y, Huang R, et al. (2017) Comprehensive analysis of ectopic mandibular third molar: A rare clinical entity revisited. Head & Face Medicine 13(1): 1-9.
27. Terauchi M, Akiya S, Kumagai J, et al. (2019) An analysis of dentigerous cysts developed around a mandibular third molar by panoramic radiographs. Dentistry Journal 7(1): 13.
28. Tournas AS, Tewfik MA, Chauvin PJ, et al. (2006) Multiple unilateral maxillary dentigerous cysts in a non-syndromic patient: A case report and review of the literature. International Journal of Pediatric Otorhinolaryngology Extra 1(2): 100-106.