

## Central Venous Line Insertion by Posterior Sternocleidomastoid Muscle Approach

**Harold Randecker MD**

*Department of Cardiothoracic Surgery, Pasadena Bayshore Hospital, Pasadena, Texas, USA*

Correspondence should be addressed to Harold Randecker, [hrendecker@earthlink.net](mailto:hrendecker@earthlink.net)

Received: January 08, 2020; Accepted: January 18, 2020; Published: January 25, 2020

### **ABSTRACT**

This research paper describes a posterior sternocleidomastoid muscle central venous line approach to either internal jugular vein which is safe efficacious and can be easily taught to any level of medical personal The technic is accompanied by diagrams showing the correct approach. The author has successfully used this technique since 1971 without complication. It can be used to place CVPs for fluid resuscitation, Swan-Ganz catheter insertion, or temporary renal dialysis.

### **KEYWORDS**

Posterior Sternocleidomastoid; Blood; CVP line

### **1. INTRODUCTION**

The research paper will describe a posterior sternocleidomastoid muscle (PSCMM) central venous line (CVP) placement technique which is rapid and requires no x-ray confirmation of the site that the tip reaches at the time of placement. This technique is completely different than the anterior sternocleidomastoid internal jugular CVP insertion technique popularized about the same time as this technique was developed. The proper final anatomic position is built into the technique. The PSCMM-CVP can be done as safely and sterilely in the hospital or the “field” as a regular peripheral intravenous line. The PSCMM-CVP line is advantageous in that it can be used at the site of occurrence: in military activity zones, in plague zones, in natural disaster/trauma zones, in initial renal hemodialysis, and in third world hospital with limited

resources which are better used on treating patients (antibiotics, HIV medication, massive fluid resuscitation, etc.) than checking CVP positions.

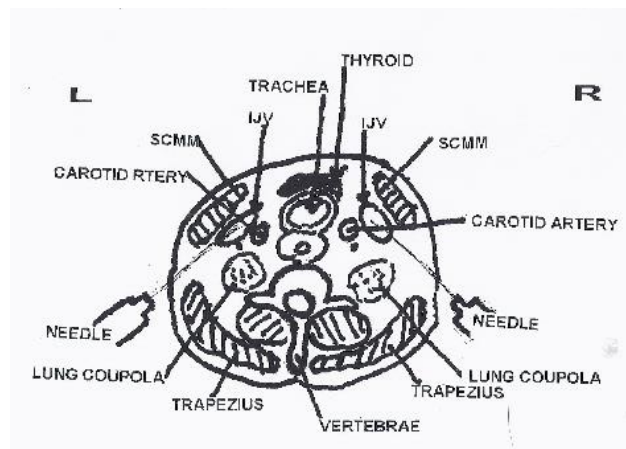
### **2. MATERIALS**

Seven Hundred (700) patients requiring CVP line, Swan Ganz catheter or temporary hemodialysis catheter placement were seen by this author from 1970 to 2006. 554 of these patients were treated using the PSCMM-CVP technique and 158 were treated with conventional subclavian vein CVPs. The PSCMM-CVPs and subclavian CVPs were done by the author both in the operating room and at the bedside in ICUs, PCUs, and on the ward. Pre and post procedure chest x-rays were obtained in 98% of the patients. This technique was easily taught to other MDs.

**Citation:** Harold Randecker, Central Venous Line Insertion by Posterior Sternocleidomastoid Muscle approach. Clin Surg J 3(3): 64-67.

### 3. METHOD

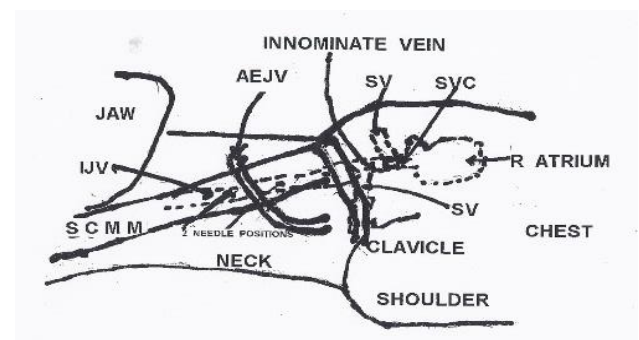
As with any CVP insertion the patient's legs must be elevated above the level of the heart by at least 1.5 to 2 feet if in the field or the patient must be in moderately steep Trendelenburg position if on a bed, tilt table or operating table. The PSCMM-CVP technique involves placing a needle in the right or left internal jugular vein (IJV) from an approach starting at the middle of the POSTERIOR border of the sternocleidomastoid muscle (SCMM) and passing the needle behind and parallel to the belly of the SCMM aiming simultaneously at the skin on top of the sternal notch. Following this path (Figure 1) the needle will intersect the internal jugular vein which is anterior and lateral to the carotid artery and the copula of the lung. The middle posterior border of the SCMM is defined by the point where the anterior external jugular vein (AEJV) crosses the posterior boarder of the SCMM. The needle can initially be inserted just above or below this spot but not through the AEJV.



**Figure 1:** Cross-sectional shows the needle insertion direction on both sides. As can be seen in the illustration, as long as the needle direction is from the posterior border of the Serno-cleidomastoid muscle and over the top of the trachea and aimed at the sternal notch, the needle falls into the internal jugular vein.

Prior to inserting the large #10 to #16 gauge CVP line needle and, after using sufficient local anesthetic at the insertion site, a #22 to #24 gauge probe needle 1" to 1 1/2" long "probe needle on a 5/10 cc syringe is used to find the

track from the skin to the IJV lumen. Once this lumen is found the probe needle is aspirated, syringe removed, needle capped, and left in place. This shows the course the large needle needs to take to safely reach the IJV lumen (Figure 2). Should the probe needle enter the internal carotid artery, bright red blood will immediately flow into the syringe with minimal aspiration suction? NO probing of this needle in the carotid artery should be attempted, and this needle should be immediately removed. Because of the small diameter of the needle no hematoma should occur. To hit the copula of the lung causing a pneumothorax, the needle must be inserted at the posterior boarder of the SCMM, aimed at a right angle to the length of the neck, and at the cervical spine which would be totally off course.



**Figure 2:** Figure shows lateral view of the neck and thorax. The insertion point is at the posterior boarder of the sternocleidomastoid muscle cephalad to the prominent superficial anterior external jugular vein and proceeds toward the thorax until the needle enters the internal jugular vein. If the internal jugular vein is missed the needle should cut into the sternocleidomastoid muscle. The catheter inserted through the needle into the internal jugular automatically proceeds to the right atrium.

On the patient's right side the SCMM-CVP line has a straight shot at the Right atrium of the heart and the line can be adjusted by sight to be in the Superior Vena Cava or the center of the atrium. This is advantageous for infusing rapidly large amounts of blood, crystalloids, and plasma without stopping the heart or doing temporary hemodialysis. Insertion of a CVP line into the left IJV will result in serpentine route for this line through the

innominate vein into the superior vena cava and into the upper atrium but still works well for monitoring catheters and rapid fluid infusion. Because the CVP insertion needle is pointed down the internal jugular vein toward the right atrium and not the pleural cavity in either IJV, the catheter tip ends up in the chest vessels >99% of the time. As both IJVs can be used for fluid/blood resuscitation, the author, on occasion, has simultaneously inserted SCMM-CVP lines in each IJV. Due to the length and diameter of the bilateral IJVs, two CVP lines each with multiple ports have been safely inserted into the same IJV without vein thrombosis or sepsis when there were no other suitable IV sites.

#### **4. RESULTS**

In 520 patients without prior history of CVP lines, the PSCMM-CVP line has resulted in no pneumothoraxes, no verifiable insertion of a line into a carotid artery, no significant neck swelling or neck hematoma; no cardiac arrest; no significant arrhythmia; no sepsis; no SVC, IJV, or atrial thrombus formation; and no neurological injury. All of these complications have been noted in the reference research papers [1-4, 7]. No catheter tip perforation of the heart occurred with any of the PSCMM-CVPs which seems to be a problem with other catheter positions [5,6]. No cardiac arrest occurred as a result of massive fluid infusion of fluids into the right atrium with any of the PSCMM-CVPs. Fibrin sheath formation was noted in some of the prolonged usage PSCMM-CVPs; these dissolved with removal of the catheter. In 120 patients without a prior history of CVP lines, the author's subclavian vein CVP lines have resulted in 7 pneumothoraxes and 21 introductions of a large needle into the subclavian artery in spite of every known precaution (none disastrous); no neurological

injuries occurred. Subclavian CVP lines were regularly found in the internal jugular vein or the opposite subclavian vein.

In 34 patients with the SCMM-CVP and 30 patients with the subclavian CVP with a history of multiple CVPs and central venous stenosis from prior catheters, ~20% from each group had the CVP line tip end up in either the innominate vein or the subclavian as the final position.

#### **5. DISCUSSION**

When the SCMM-CVP is applied as described in the text and the two diagrams, I have found no pressing need for a chest x-ray for position or complications. When faced with mass casualty situations (war injuries, natural disasters, plagues, dysenteries, and trauma), hemodialysis, and the need to give toxic drugs centrally for cancers, the SCMM-CVP might give the patient a better chance at survival. This technique needs a multi-center clinical trial to prove its efficacy in the hands of surgeons, internists, cardiologists, infectious disease specialists, emergency room MDs, EMTs, ARNPs, RNs, LVNs, Physicians' Assistants, and others. These trials can take place in any location around the world.

#### **6. CONCLUSION**

This research paper describes a posterior sternocleid-omastoid muscle central venous line approach to either internal jugular vein which is safe efficacious and can be easily taught to any level of medical personal. The technic is accompanied by diagrams showing the correct approach. The author has successfully used this technique since 1971 without complication. It can be used to place CVPs for fluid resuscitation, Swan-Ganz catheter insertion, or temporary renal dialysis.

#### **REFERENCES**

1. Raad II, Luna M, Khalil SA, et al. (1994) Body CP. The relationship between thrombotic and infectious complications of central venous catheters. *Journal of the American Medical Association* 271(13): 1014-1016.

2. Dunbar RD, Mitchell R, Lavine M (1981) Aberrant locations of central venous catheters, *Lancet* 317(8222): 711-15.
3. Rooden CJ, Tesselaar ME, Oscanto S, et al. (2005) Deep vein thrombosis associated with central venous catheters-a review. *Journal of Thrombosis and Haemostasis* 3(11): 2409-2419.
4. McGee DC, Gould MK (2003) Preventing complications of central venous catheterization, *The New England Journal of Medicine* 348(12): 1123-33.
5. Fletcher SJ, Bodenham AR (2000) Editorial II: Safe placement of central venous catheters: where should the tip of the catheter lie. *British Journal of Anaesthesia* 85(2): 188-119.
6. Vesely TM (2003) Central venous catheter tip position: a continuing controversy, *Journal of Vascular and Interventional Radiology* 14(5): 527-34.
7. Timsit JF, Farcas JC, Boyer JM, et.al. (1998) Central venous catheter related thrombosis in intensive care patients: incidence, risk factors, and relationship with catheter-related sepsis. *Chest* 114(1): 207-213.