

## ANK Therapeutic Prospects and Usefulness of PD-L1 and NK Activity as Biomarkers for Predicting Treatment Efficacy Revealed from the Treatment Course of Patients with HTLV-1-Associated Bronchioloalveolar Disease

Kenjiro Nagai<sup>1,2\*</sup>, Syo Nagai<sup>1</sup>, Yuji Okubo<sup>3</sup> and Keisuke Teshigawara<sup>3</sup>

<sup>1</sup>Medical Corporation Ebino Centro Clinic, Ebino City, Miyazaki Prefecture, Japan

<sup>2</sup>Department of Medicine, Respiratory Disease Center, Yokohama City University School of Medicine, Yokohama City, Kanagawa Prefecture, Japan

<sup>3</sup>Higashinotoin Clinic, Kyoto City, Kyoto Prefecture, Japan

Correspondence should be addressed to Kenjiro Nagai, Medical Corporation Ebino Centro Clinic, 1007-4 Uwae, Ebino City, Miyazaki Prefecture, 889-4304, Japan

Received: August 30, 2022; Accepted: September 06, 2022; Published: September 13, 2022

### ABSTRACT

Adult T-cell leukemia/lymphoma (ATL) is a peripheral T-cell neoplasm with poor prognosis that can present as HTLV-1-associated bronchioloalveolar disease (HABA). Chemotherapy is recommended for ATL; however, it is not very effective against all types of ATL. Furthermore, there are no effective treatments for smoldering HABA-associated ATL. We present a case in which amplified natural killer cell (ANK) therapy was effective in a woman in her early 80s who was previously diagnosed with ATL-related smoldering HABA and presented with dyspnea and productive cough on exertion. The symptoms were suppressed for approximately 10 months after the first treatment, but then gradually worsened. About a year later, a second treatment was followed by mild side effects. Suppression of ATL cell proliferation by repeated doses of ANK therapy appears to be effective in this patient. The therapeutic effect was high even with long treatment intervals, and the efficacy and safety of repeated treatments have been demonstrated. ANK therapy is expected to be the mainstay of treatment ATL and HABA. ANK therapy has been reported to kill PD-L1 positive tumor cells and some solid tumors with excellent responses have many PD-L1-positive tumor cells. ANK therapy is thought to be effective for ATL because there are many PD-L1-positive tumor cells. Furthermore, administration of activated NK cells may increase tumor-killing activity in those patients with reduced NK activity. While future studies are needed, PD-L1 positive rate and NK activity may be biomarkers for the effectiveness of ANK therapy.

### **KEYWORDS**

Adult T-cell leukemia; HTLV-1-related bronchiolo-alveolar disorder; ANK therapy; Diffuse panbroncheolitis; PD-L1; Activated NK

**Citation:** Kenjiro Nagai, ANK Therapeutic Prospects and Usefulness of PD-L1 and NK Activity as Biomarkers for Predicting Treatment Efficacy Revealed from the Treatment Course of Patients with HTLV-1-Associated Bronchioloalveolar Disease. J Can Med Met 6(1): 30-36.

## **INTRODUCTION**

Adult T-cell leukaemia (ATL) is a peripheral T-cell tumor with a poor prognosis that develops in carriers of human T-cell leukaemia virus type 1 (HTLV-1) [1,2]. According to the diagnosis guide of the Ministry of Health and Welfare Specific Disease Research Group, there are cases of ATL that present as diffuse panbroncheolitis (DPB) and during the course of idiopathic interstitial pneumonia (IIP); these pathological conditions are collectively named HTLV-1-associated bronchiolo-alveolar disorder (HABA) [3]. There are four types of ATL: Acute, lymphoma, chronic, and smoldering types. These four types are further classified as follows: acute/lymphoma type and chronic ATL with a poor prognosis as aggressive ATL; and chronic/smoldering type without a poor prognosis as painless ATL, each with their own preferred treatment options [4].

Aggressive ATL has a very poor prognosis with a median survival of approximately 10 months. Multidrug chemotherapy, and if possible, allogeneic hematopoietic stem cell transplantation may be administered, considering age and general condition. Smoldering ATL is treated with topical treatments such as corticosteroids, external retinoids, local radiation therapy, and photochemotherapy of skin lesions. Systemic treatments include systemic administration of steroid hormones, oral retinoids, interferon- $\gamma$ , and single-agent chemotherapy. However, they have little effect on prolonging survival and have strong side effects. The current form of amplified natural killer cell (ANK) immunotherapy is different from conventional immunotherapy in that it focuses on the strong anti-cancer effect of natural killer (NK) cells from various lymphocytes [5,6]. In this method, NK cells are taken from the patient's blood, cultured to specifically enhance their cancer-fighting function, and returned to the patient's body to start treatment. This method is generally considered to be effective against all cancers [7].

Here, we report the treatment protocol of two rounds of ANK therapy for an elderly woman diagnosed with HABA secondary to smoldering ATL.

## **CASE PRESENTATION**

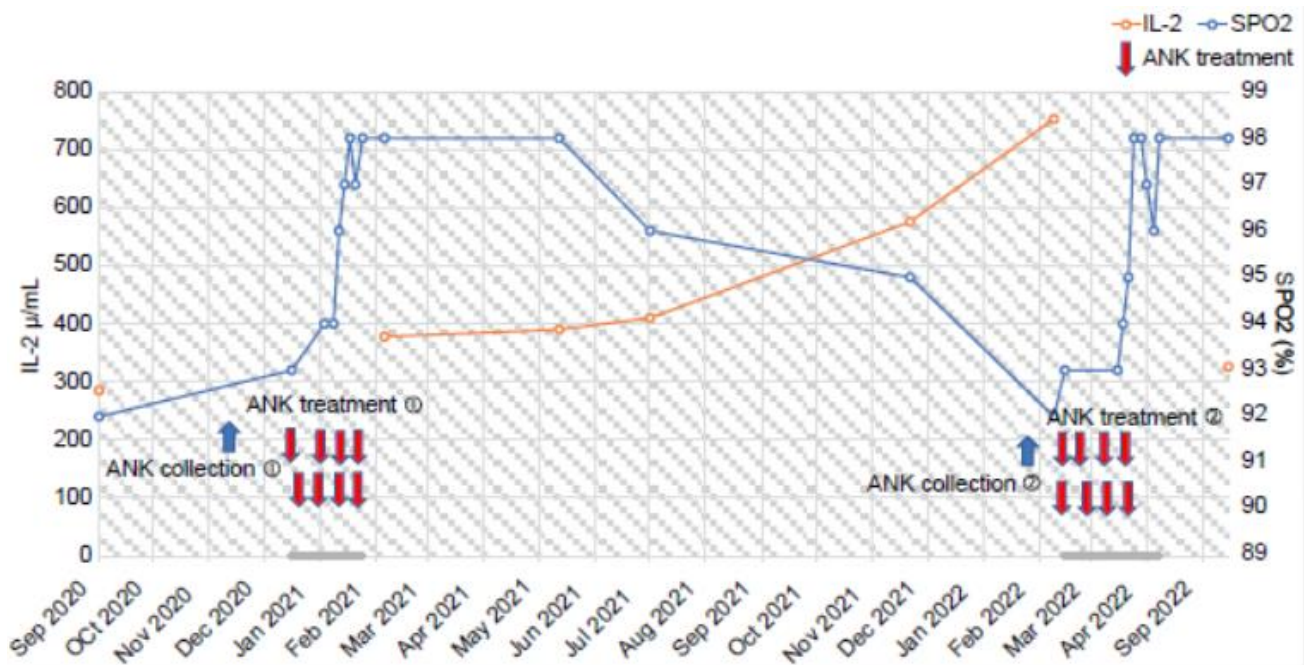
Ethical approval to report this case was obtained from the Ebino Centro Clinic Ethics Committee (Approval Number: No. 2). Written informed consent was obtained from the patient for their anonymized information to be published in this article.

The patient completed eight courses of 1<sup>st</sup> line ANK therapy in January 2021. The treatment was very effective, with improvement in respiratory function, chest CT, and symptoms of dyspnea. During the treatment, she had mild fever and malaise, but was able to complete all eight courses as an outpatient. However, beginning around July 2021, dyspnea on exertion and cough gradually appeared. Since no significant decrease in oxygen saturation (SpO<sub>2</sub>) was observed, the patient was followed up. However, exertional dyspnea and cough gradually worsened and repeat chest CT showed diffuse exacerbation of granular opacities in both lung fields. Her respiratory capacity (VC) also decreased from 1.54 L to 1.00 L. At the patient's request, a second ANK collection was performed in January 2022. Results of blood tests, sputum cultures (Table 1), and pulmonary function tests performed immediately before the second treatment were similar to those immediately before the first treatment (Table 2). Interleukin-2 (IL-2) was also increased and SpO<sub>2</sub> was decreased (Figure 1). A whole-body CT showed no lymphadenopathy, but multiple nodular opacities reminiscent of DPB were observed in the lungs similar to before the first treatment (Figure 2 and Figure 3).

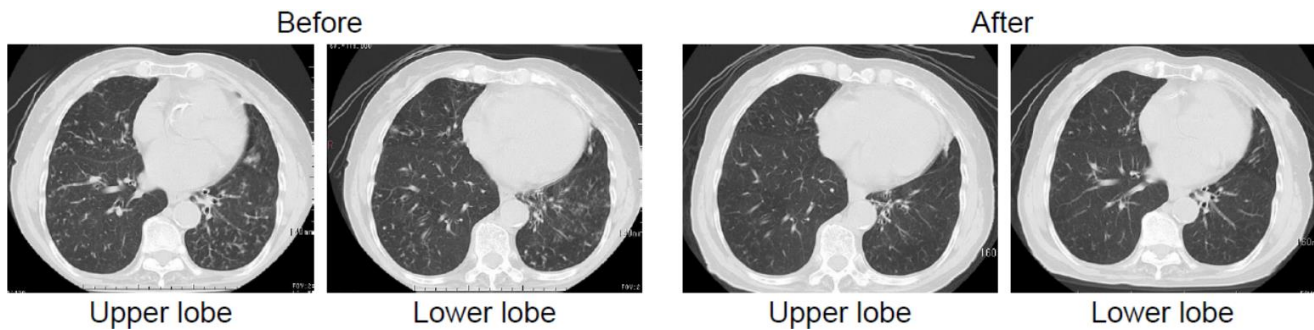
As with the previous round of treatment, four samples of blood were taken in preparation for ANK therapy in

February 2022 in order to activate and amplify NK cells in a lymphocyte bank. The samples were diluted in a 1:2 ratio and administered via injection twice a week, starting in

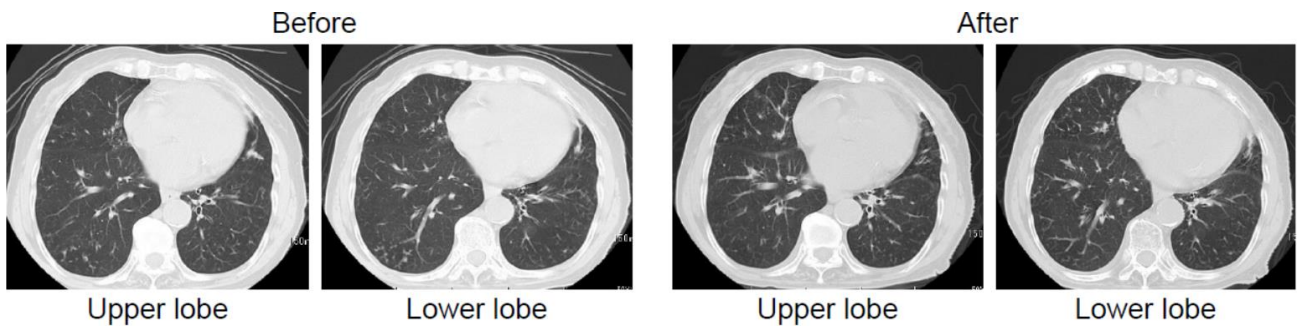
March (Figure 1). All eight treatment courses were provided on an outpatient basis.



**Figure 1:** Treatment course from after the first treatment to after the second treatment.  
**Note:** ANK: Amplified Natural Killer Cells; SpO<sub>2</sub>: Oxygen Saturation; IL-2: Interleukin-2.



**Figure 2:** Chest computed tomography findings before and after the first treatment.



**Figure 3:** Chest computed tomography findings before and after the second treatment.

Haematology			Serology		
Value	Unit		Value	Unit	
White blood cells	9430	/ $\mu$ L	KL-6	177	u/mL
Neutrophils	57	%	sIL-2	753	u/mL
Lymphocytes	39	%	IgG	1945	mg/dL
Mononuclear cells	4	%	IgA	341	mg/dL
Eosinophils	0	%	IgE	4	IU/mL
ATL cells	5	%	HTLV-1 Ab	(+)	
Flower cell	0	%	HTLV-1 LIA	(+)	
Red blood cells	$3.87 \times 10^6$	/ $\mu$ L	P.19 Ab	(+)	
Haemoglobin	11.6	g/dL	P.24 Ab	(+)	
Platelets	$184 \times 10^3$	/ $\mu$ L	P.46 Ab	(+)	
			P.21 Ab	(+)	
Biochemistry			T-SPOT	(-)	
Total protein	7.1	g/dL	$\beta$ -D glu	2.5	pg/mL
Albumin	4	g/dL			
Blood urea nitrogen	18.6	mg/dL	Microbiology		
Creatinine	0.62	g/dL	Intratracheal sputum bacteria culture		
Ca	9.2	g/dL	MSSA ( <i>Staphylococcus aureus</i> )		
Immunoprecipitin	3	g/dL	Intratracheal sputum acid-fast bacilli culture		
Total bilirubin	0.8	mg/dL	Non-tuberculous mycobacteriosis PCR test		
Aspartate aminotransferase	24	U/L	<i>Mycobacterium avium</i>		
Alanine transaminase	14	U/L	<i>M. intracel</i>		
Alkaline phosphatase	162	U/L			
$\gamma$ -glutamyl transferase	23	U/L			
Na	141	mmol/L			
K	3.8	mmol/L			
Cl	104	mmol/L			
Creatine kinase	75	U/L			
C-reactive protein	0.28	mg/dL			
Lactate dehydrogenase	187	U/L			

**Table 1:** Laboratory data immediately before the second round of treatment.

1 <sup>st</sup> Round of Therapy	Before Treatment		After Treatment	
	Measured Value	% Predicted Value	Measured Value	% Predicted Value
VC	0.93 L	46.5	1.54 L	78.6 %
FVC	0.88 L	44	1.18 L	60.2 %
FEV <sub>1</sub>	0.83 L	57.6	1.12 L	82.4 %
FEV <sub>1</sub> %	94.32 %	127	94.92 %	128.5 %
2 <sup>nd</sup> Round of Therapy	Before Treatment		After Treatment	
	Measured Value	% Predicted Value	Measured Value	% Predicted Value
VC	1.00 L	53.8 %	1.14 L	62.0 %
FVC	0.86 L	50.3 %	1.03 L	60.9 %
FEV <sub>1</sub>	0.79 L	61.2 %	0.94 L	74.0 %
FEV <sub>1</sub> %	91.86 %	117.9 %	91.26 %	117.5 %

**Table 2:** Pulmonary function test results.

## **OUTCOME AND FOLLOW-UP**

Cough, sputum production, dyspnea, and SpO<sub>2</sub> have improved since the fourth course of the second round of ANK therapy (Figure 1).

Approximately a month after treatment, chest CT showed a tendency of the diffuse granular shadows to improve compared to before treatment, although it was not as prominent as after the first round of treatment (Figure 3). Moreover, the symptoms of exertional dyspnea, cough, and sputum production improved.

On respiratory function testing, VC of 1.54 L after the first treatment decreased to 1.00 L before the second treatment and improved to 1.24 L after the second treatment (Table 2). Serologic testing also showed that IL-2 had increased to 753 U/mL after the first round of treatment, which decreased to 426 U/mL after the second round of treatment (Figure 1). During the first round of treatment, general malaise and mild fever developed after the infusion, resulting in the patient needing to occasionally rest at home. Although general malaise developed in the second round of treatment, it was milder than before and hardly

any fever occurred. No other serious side effects were reported, and the patient was able to complete eight outpatient treatments.

After the second treatment, symptoms, respiratory function tests, CT findings, and serologic tests all suggested a trend toward remission.

## **DISCUSSION**

This is the first report of HABA-B being treated twice with ANK therapy in Japan, with the treatment course and side effects followed-up for approximately 1 year.

As for the pulmonary complications of ATL, lung lesions such as alveolar inflammation of T lymphocytes, lymphocytic interstitial pneumonia, and various organ disorders may occur due to the cell damage mechanism of CD8+ T lymphocytes, even when opportunistic infections associated with ATL lung infiltration and immunosuppression do not develop.

The mechanisms of lung lesions caused by HTLV-1 are considered as follows: 1) G1 (growth) phase arrest of T-cells by the viral tax gene, 2) anti-apoptotic effect by NF- $\kappa$ B activation, or 3) inhibition of DNA damage repair by p53 suppression. HTLV-1 mainly infects CD4+ T lymphocytes and the alveolar epithelium, which activates NF- $\kappa$ B, causing HTLV-1-related lung disease [8-10].

Cases of secondary lymphocytic interstitial pneumonia of HTLV-1 carriers, small-ring ATL hypersensitivity pneumonia, and this case, have been reported as HTLV-1-related lung disease. These lung lesions are classified into DPB-type and IIP-type [11-13]. However, there is currently no established diagnostic method or classification. Recently, it has been reported that the p40(tax) gene of HTLV-1 is associated with lung lesions [14-16].

With the ANK therapy used for treatment, ATL leukaemia cells express T-cell and co-stimulatory markers of NK cells such as CD80 and CD137L. Simultaneously, ATL cells have characteristics of regulatory T-cells, which cause immunosuppression in patients with ATL. This implies that ATL cells express both co-stimulatory and inhibitory molecules such as programmed death-ligand 1 (PD-L1). Natural killer cells extracted from blood, then cultured and activated, can attack tumors, regardless of tumor suppressor expression, compared to T cells. Therefore, ANK therapy is tumor cell-specific, with a low risk of significant damage to the normal immune system; it has been reported to be able to kill cells. Kataoka and Ogawa et al. reported that deletions and amplifications of the CD274 3'-untranslated region (UTR) (encoding PD-L1) were frequently observed in his ATL, leading to significantly elevated PD-L1 expression. reportedly accepted. Therefore, the treatment is considered effective.

Serious side effects have been observed with the commonly used anti-CC chemokine receptor 4 (CCR4) antibody, yet there are no reports of serious side effects for ANK therapy [17-19], which may be simple to use for the above reasons. Additionally, other cancers frequently have genomic abnormalities similar to ATL, including diffuse large-cell lymphoma, gastric, esophageal, and cervical cancers [20]. These findings suggest that repeated doses of NK cells, including ANK cells, alleviate immunosuppression via the PD-1–PD-L1 pathway [21,22]. Due to these two mechanisms, ANK therapy for ATL is considered to be very effective. Amplified NK therapy is likely to be similarly effective for cancers with high PD-L1 expression. For solid tumors, PD-L1 levels may be considered a biomarker for predicting therapeutic effect. Further research is required to prove this hypothesis.

There is currently no cure for smoldering ATL. Chemotherapy is indicated for the acute type, but it is not effective and has strong side effects. Therefore, treatment

with ANK therapy, which is considered to be highly effective with a low risk of side effects, was selected. After treatment, the patient's symptoms (e.g., cough, expectoration, dyspnea), pulmonary function tests, and chest CT showed dramatic improvement.

CD274 3'-UTR aberrations are frequently observed in ATL. A significantly higher expression of PD-L1 has been reported. ANK cells can kill PD-L1 tumor cells. It has also been established that the proportion of NK cells with the CD16+/CD56+ phenotype is significantly lower in carriers infected with HTLV-1. It is for these two reasons that administration of NK cells with enhanced activation by ANK therapy is hypothesized to be highly effective in ATL.

According to findings 7, repeated administration of ANK therapy appears to be effective in suppressing ATL cell proliferation. Even if the treatment interval is long, the treatment effect is high. Efficacy and safety with repeated treatments have been proven even in the elderly. In the future, ANK therapy may become the main treatment ATL and HABA. ANK therapy is said to be effective against all

cancers, but it may be a particularly effective and safe treatment for PD-L1-producing cancers. Further studies are needed to prove its efficacy as a biomarker for other PD-L1-expressing cancers. In addition, for the reasons mentioned above, it is mechanistically predicted that ANK therapy will also have a high therapeutic effect in patients with decreased NK activity. This allows lymphocyte bank Co., Ltd., which provided the ANK therapy, to measure NK activity. In the future, it will be necessary to examine whether NK activity can be used as a biomarker for predicting the therapeutic efficacy of ANK therapy for ATL and solid tumors.

### **ACKNOWLEDGEMENT**

The authors would like to thank the lymphocyte bank for providing ANK therapy.

### **FUNDING**

This research received no specific grant from any funding agency in the public, commercial, or not-for-profit sectors.

### **CONFLICT OF INTEREST**

The authors have no conflicts of interest to declare.

### **REFERENCES**

- 1) Yodoi J (1974) Two cases of T-cell chronic lymphocytic leukemia in Japan. *The New England Journal of Medicine* 290: 572-573.
- 2) Uchiyama T, Yodoi J, Sagawa K, et al. (1977) Adult T-cell leukemia: Clinical and hematologic features of 16 cases. *Blood* 50(3): 481-492.
- 3) Kadota JI, Mukae H, Fujii T, et al. (2004) Clinical similarities and differences between human T-cell lymphotropic virus type 1-associated bronchiolitis and diffuse panbronchiolitis. *Chest* 125(4): 1239-1247.
- 4) Takatsuki K, Yamaguchi K, Kawano F, et al. (1985) Clinical diversity in adult T-cell leukemia-lymphoma. *Cancer Research* 45(9\_Supplement): 4644s-4645s.
- 5) Rosenberg S (1985) Lymphokine-activated killer cells: A new approach to immunotherapy of cancer. *Journal of the National Cancer Institute* 75(4): 595-603.
- 6) Ishikawa T, Imawari M, Moriyama T, et al. (1988) Immunotherapy of hepatocellular carcinoma with autologous lymphokine-activated killer cells and/or recombinant interleukin-2. *Journal of Cancer Research and Clinical Oncology* 114(3): 283-290.

- 7) Teshigawara K, Nagai S, Bai G, et al. (2018) Successful amplified-natural-killer cell (ANK) therapy administered to a patient with smoldering adult T-cell leukemia in acute crisis. *Reports* 1(2): 13.
- 8) Liu M, Yang L, Zhang L, et al. (2008) Human T-cell leukemia virus type 1 infection leads to arrest in the G1 phase of the cell cycle. *Journal of Virology* 82(17): 8442-8455.
- 9) Teruya H, Tomita M, Senba M, et al. (2008) Human T-cell leukemia virus type I infects human lung epithelial cells and induces gene expression of cytokines, chemokines and cell adhesion molecules. *Retrovirology* 5(1): 1-10.
- 10) Yoshida M, Suzuki T, Fujisawa J, et al. (1995) HTLV-1 oncoprotein tax and cellular transcription factors. *Transacting Functions of Human Retroviruses* 93: 79-89.
- 11) Tateishi U, Nishihara H, Miyasaka K (2001) HTLV-1-associated bronchopneumonopathy (HAB): CT-pathological correlation. *Clinical Radiology* 56(8): 664-666.
- 12) Matsuo K, Tada S, Kataoka M, et al. (2000) Bronchiolitis obliterans organizing pneumonia (BOOP) in a case of smoldering adult T-cell leukaemia. *Respirology* 5(1): 81-85.
- 13) Kimura I (1988) HTLV-1 associated bronchiolo-alveolar disorder (HABA). *Nihon Kyobu Rinsho* 47: 283-293.
- 14) Nagai K, Nagai S, Hara Y (2021) Successful treatment of smoldering human T cell leukemia virus type1 associated bronchiolitis and alveolar abnormalities with amplified natural killer therapy. *BMJ Case Reports* CP 14(12): e244619.
- 15) Higashiyama Y, Katamine S, Kohno S, et al. (1994) Expression of human T lymphotropic virus type 1 (HTLV-1) tax/rex gene in fresh bronchoalveolar lavage cells of HTLV-1-infected individuals. *Clinical & Experimental Immunology* 96(2): 193-201.
- 16) Sugimoto M, Kitaichi M, Ikeda A, et al. (1998) Chronic bronchioloalveolitis associated with human T-cell lymphotropic virus type I infection. *Current Opinion in Pulmonary Medicine* 4(2): 98-102.
- 17) Ishida T, Ito A, Sato F, et al. (2013) Stevens-Johnson syndrome associated with mogamulizumab treatment of adult T-cell leukemia/lymphoma. *Cancer Science* 104(5): 647-650.
- 18) Mohammed TO, Chagan-Yasutan H, Ashino Y, et al. (2017) Galectin-9 as a predictive marker for the onset of immune-related adverse effects associated with anti-CCR4 MoAb therapy in patients with adult T cell leukemia. *The Tohoku Journal of Experimental Medicine* 241(3): 201-208.
- 19) Ratner L, Waldmann TA, Janakiram M, et al. (2018) Rapid progression of adult T-cell leukemia-lymphoma after PD-1 inhibitor therapy. *New England Journal of Medicine* 378(20): 1947-1948.
- 20) Kataoka K, Ogawa S (2016) Genetic biomarkers for PD-1/PD-L1 blockade therapy. *Oncoscience* 3(11-12): 311.
- 21) Lanuza PM, Viguera A, Oliván S, et al. (2018) Activated human primary NK cells efficiently kill colorectal cancer cells in 3D spheroid cultures irrespectively of the level of PD-L1 expression. *Oncoimmunology* 7(4): e1395123.
- 22) Prince HE, Jackson AL (1990) Normal expression of p55 interleukin 2 receptors (CD25) by lymphocytes from former blood donors seropositive for human T lymphotropic virus. *Clinical Immunology and Immunopathology* 57(3): 459-464.