Clinical Surgery Journal

Case Report | Vol 4 Iss S7

The Face of the COVID-19 Pandemic: Invasive Rhino-Orbital Mucormycosis

Stuti Chowdhary, Lokesh Kumar Penubarthi*, Sunil Kumar Saxena and Arun Alexander

Department of Otorhinolaryngology (E.N.T.), Jawaharlal Institute of Postgraduate Medical Education and Research (JIPMER), Puducherry, India

Correspondence should be addressed to Lokesh Kumar Penubarthi, lokesh86p@gmail.com

Received: April 26, 2021; Accepted: May 23, 2021; Published Date: May 30, 2021

ABSTRACT

BACKGROUND

Mucormycosis, in its acute invasive form, is known to be one of the most rapidly progressive infectious diseases, often with fatal consequences in the absence of timely medical and surgical interventions. The angio-invasive nature of the fungus can rapidly cause extreme necrosis and sloughing, with the possibility of intracranial spread and hence mortality. Despite wide disease clearance and anti-fungal therapy, outcomes can be variable. The degree of immunosuppression influences the rapidity of the fungal spread in such cases.

CASE REPORT

Presented here is a patient of extensive rhino-orbital mucormycosis, who underwent prompt reversal of ketoacidosis and surgical debridement under the cover of liposomal Amphotericin B. A planned reconstruction procedure was undertaken after a suitable interval when active infection was controlled. Despite adequate management in the intensive care unit, the patient succumbed to multi-organ failure secondary to sepsis.

CONCLUSIONS

A possibility of variable outcomes exists, even in cases with a prudent management plan. A high index of suspicion should be maintained, especially in cases of localizing sino-nasal symptoms, for early microbiological confirmation and treatment. Mortality remains high for mucormycosis in general. This case represents the most disfiguring of the presentation of such diseases. The cosmetic outcome needs to be balanced with the disease clearance for optimum patient benefit.

KEYWORDS

COVID19; Mucormycosis; Facial debridement

INTRODUCTION

Rhino-orbital mucormycosis is one of the most acute, rapidly progressive, and morbid emergencies seen by the otolaryngologist. Lowered host defences, combined with the fungi's angio-invasive ability, contribute to the high fatality of this condition in the absence of prompt surgical debridement and medical management. Here is the case of a patient with disseminated rhino-orbital mucormycosis, who presented in bad shape during the ongoing COVID-

Citation: Stuti Chowdhary, The Face of the COVID-19 Pandemic: Invasive Rhino-Orbital Mucormycosis. Clin Surg J 4(S7): 14-17.

© 2021 The Authors. Published by TRIDHA Scholars.

19 pandemic and was managed aggressively in a multidisciplinary approach because of underlying ketoacidosis. A high index of suspicion and combined medical-surgical therapy is imperative, especially in geographical areas known to be endemic for the condition.

CASE REPORT

A 45-years-old diabetic woman arrived at the ENT emergency room with right-sided widespread soft tissue necrosis of the face and sudden, painful, and complete loss of vision in the right eye for seven days. There was no associated blood-stained nasal discharge or loosening of teeth in the upper jaw. On examination, there was massive sloughing in the peri and infra-orbital region, crusts in the nasal cavity, and extensive hard palatal necrosis. There was no apparent cervical lymphadenopathy. She was in diabetic ketoacidosis with random blood glucose over 339 mg/dl. She tested negative for COVID-19 by RT-PCR. She had normal liver and kidney function on presentation (Figure 1).

Figure 1: Clinical photograph of the patient before undertaking the flap reconstruction procedure, after extensive debridement and right orbital exenteration.

Potassium hydroxide (KOH) mount of the crusts from the nasal cavity revealed broad aseptate hyphae with wide-angled branching. A contrast-enhanced CT scan of the paranasal sinuses and orbit showed soft tissue density in the right-sided maxillary, ethmoids, and sphenoid sinuses and within the right orbit due to the erosion of lamina papyracea. Extensive subcutaneous edema was noted, suggestive of extension of the infection into the sub-fascial planes of the right mid-face. A C-reactive protein level of 0.6 mg/dL on admission effectively ruled out bacterial infection of the facial soft tissue. A clinical diagnosis of invasive rhino-orbital mucormycosis was thus made (Figure 2 and Figure 3).

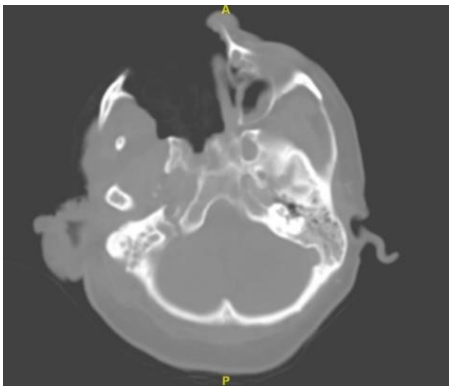

Figure 2: Computed tomography (CT) axial section in the bone window, depicting the radiological defect after hemifacial debridement, right-sided maxillectomy, and right orbital exenteration.

Figure 3: Postoperative clinical photograph after undergoing anterolateral thigh flap to cover the hemifacial defect.

The patient underwent aggressive management of blood sugar and acidosis on admission. She underwent an emergency debridement and orbital exenteration, with an elective tracheostomy and a feeding gastrostomy (Figure 1).

The patient was mechanically ventilated in the critical care unit for 20 days and started on intravenous Liposomal Amphotericin B and broad-spectrum antibiotics. A postoperative CT scan was ordered to look for residual disease (Figure 2). The wound underwent repeated dressing for 30 days when the patient was deemed fit to undergo a lengthy surgical procedure. The patient underwent reconstruction of the defect with a free anterolateral thigh flap (Figure 3). She had a stormy postoperative course with multi-drug resistant sepsis. Her serum procalcitonin levels spiked to 10.95 ng/mL despite the administration of culture-directed intravenous antibiotics. She succumbed to the same after a prolonged intensive care unit stay of over two months.

DISCUSSION

Mucormycosis presents most commonly as the rhino-orbital-cerebral (ROC) form, though other manifestations such as pulmonary, cutaneous, gastro-intestinal, disseminated, and rare forms have been described [1,2]. The acute invasive rhino-orbital form is a potentially fatal fungal infection of the nose, paranasal sinuses, and the orbit, often involving the intracranial compartment and the facial soft tissues of immunocompromised hosts. A low survival rate of 36%-42% [3] with a delay in initiating treatment makes it one of the most dangerous ENT emergencies. Extensive angioinvasion calls for aggressive debridement, prompt initiation of anti-fungal medication, and reversal of the immuno-suppressed state. Hyperglycaemia and ketoacidosis secondary to uncontrolled diabetes mellitus is the leading cause of death in mucormycosis. There is decreased phagocyte function, macrophage motility and reduction in myeloperoxidase activity in diabetic ketoacidosis, which favors blood vessel invasion by fungi leading to the intraluminal microthrombi formation [4]. This compromises oxygenation, allowing the fungi to thrive and spread.

During the ongoing COVID-19 pandemic, with the restrictions on travel, many patients had reduced access to their regular medications, including oral and injectable hypoglycaemic agents as seen in our patient. The existing milieu of such a hyperglycemic state hastens the process of invasion with inhalation or traumatic implantation of fungal spores. Extension to the orbit is usually through a breach of the lamina papyracea, after involving the ethmoid sinus complex. Fungi of the *zygomycetes* family are primarily implicated in the ROC form, which rapidly involves arteries, musculo-fascial planes, and even bone. A high index of suspicion, clinical and microbiological diagnosis, and immediate combined medical and surgical treatment is the mainstay of management. An urgent debridement allows for a reduction of the fungal load, generates a specimen for culture and histopathology, and changes the micro-aerophilic tissue environment that potentiates fungal spread. Nasal crusts are relatively easy to obtain for fungal mounts to reach a tissue diagnosis. Mounts stained with Gomori Methenamine Silver (GMS) and potassium hydroxide (KOH) should be used to accurately diagnose and pinpoint the fungal morphology. It is prudent to send some tissue from the margins of the wound for histopathological examination and immunohistochemistry to rule out malignancies and lethal midline granuloma.

Since the extensive debridement almost involving the right half of the face was inevitable, reconstruction options were assessed keeping in mind the cosmetic, functional, and socio-emotional aspects. We chose autologous tissue in preference to primary prosthetic implantation as it gives better muscle bulk, is more robust, and allows an acceptable return of speech and swallowing functions [5]. Flap reconstruction has been widely reported in the literature [6], but this was a concern in this patient due to

the precarious residual microvasculature of the recipient bed.

Due to the widespread facial necrosis and skin involvement in the midfacial region, the differential diagnosis of necrotizing fasciitis and lethal midline granuloma was considered. A lack of an antecedent history of trauma ruled out the former. Malignancy of the maxillary sinus was also considered.

CONCLUSIONS

COVID-19 pandemic has indirectly influenced chronic ailments like diabetes, hypertension, chronic kidney disease and other systemic diseases. Because of poor access to health care during the COVID-19 pandemic, there was a rise in the complication rate secondary to chronic ailments, especially those with diabetes. Uncontrolled and improperly treated diabetes mellitus with an underlying ketoacidosis state is a risk factor for fungal invasion and proliferation. The strict control of blood sugars is imperative to prevent disseminated mucormycosis. Microbiological diagnosis for fungal morphology and culture is the gold standard. Early clinical diagnosis and surgical debridement are the keys to survival, given the high mortality of the condition.

GRANT INFORMATION AND SOURCES OF SUPPORT

This research did not receive any specific financial aid from funding agencies in the public, commercial, or not-for-profit sectors.

PERMISSION TO GRANT A BLIND REVIEW

The authors agree to grant a blind review for this paper as per the discretion of the Editor. This has been discussed and agreed to by all the authors.

CONFLICT OF INTEREST

The authors declare that there is no conflict of interest regarding the publication of this article.

REFERENCES

1. Prakash H, Chakrabarti A (2019) Global epidemiology of mucormycosis. Journal of Fungi (Basel) 5(1): 26.
2. Roden MM, Zaoutis TE, Buchanan WL, et al. (2005) Epidemiology and outcome of zygomycosis: A review of 929 reported cases. Clinical Infectious Disease 41(5): 634-653.
3. Karadeniz Uğurlu Ş, Selim S, Kopar A, et al. (2015) Rhino-orbital mucormycosis: Clinical findings and treatment outcomes of four cases. Turkish Journal of Ophthalmology 45(4): 169-174.
4. Spellberg B, Edwards J Jr, Ibrahim A (2005) Novel perspectives on mucormycosis: Pathophysiology, presentation, and management. Clinical Microbiology Reviews 18(3): 556-569.
5. Srikanth V, Pradeep KN, Anantheswar YN, et al. (2020) Cranio-facial mucormycosis - The plastic surgeon's perspective. European Journal of Plastic Surgery 43 : 239-246.
6. Reinbold C, Derder M, Hivelin M, et al. (2016) Using free flaps for reconstruction during infections by mucormycosis: A case report and a structured review of the literature. Annales de Chirurgie Plastique et Esthétique 61(2): 153-161.