

Practique Clinique et Investigation

Socket Shield Technique: A Novel Approach for the Esthetic Rehabilitation of Edentulous Maxillary Anterior Alveolar Ridges: A Special Case File

Abhishek Nayyar*

Department of Oral Medicine and Radiology, Saraswati-Dhanwantari Dental College and Hospital and Post-Graduate Research Institute, Parbhani, Maharashtra, India

*Correspondence: Abhishek Singh Nayyar, Department of Oral Medicine and Radiology, Saraswati-Dhanwantari Dental College and Hospital and Post-Graduate Research Institute, Parbhani, Maharashtra, India, Tel: +91-9850904067; E-mail: singhabhishekndls@gmail.com

ABSTRACT

Implant placement in maxillary anterior region has always been challenging for the implantologists. Different levels of gingival display along with the uncertainty of soft and hard tissue changes post-extraction make things highly predictable in this part of the alveolar ridges. This difficulty is augmented by the patient's desire to have teeth in this aesthetic zone immediately. Researchers have devised certain techniques to address this issue and one such method of an immediate, highly esthetic rehabilitation is called as the Socket Shield Technique. The use of cortical engagement in this region along with socket shield technique gives the operator an opportunity to immediately load the prosthesis with optimal esthetic outcomes. Another challenging issue secondary to implant therapy is peri-implant infections including the commoner peri-implantitis. The presence of rough implant surfaces, when exposed to oral environment, lead to the formation of a kind of nidus which, further, feeds soft and hard tissue loss. Presence of a peri-apical pathology from previous dentition may, also, infect the implant surface. An attempt was made in this case to utilize the Socket Shield Technique along with provision of smooth-surfaced dental implants, stabilized with cortical engagement, for the replacement of missing maxillary anterior teeth.

Keywords: *Socket shield technique; Novel approach; Esthetic rehabilitation; Edentulous; Maxillary anterior alveolar ridges; Immediate loading; Implant prosthesis; Peri-implant infections; Peri-implantitis; Smooth surface dental implants*

INTRODUCTION

Edentulous maxillary anterior region poses a challenge to the operator as different levels of lip line along with different tissue biotypes make post-extraction tissue changes highly unpredictable [1]. The existing literature is devoid of studies supporting complete tissue preservation and immediate implant placement. Post-extraction tissue changes are always expected and unpredictable and this uncertainty is best understood by the classification given by Joseph YK Kan et al. [2] which describes the relationship between the housing of roots in the alveolar bone and the eventual resorption patterns expected or, seen. Historically, attempts have been made to control these changes using the pontic shield technique and the root submergence technique. Socket shield technique is one such procedures towards this effort of complete tissue

Citation: Abhishek Nayyar, Socket Shield Technique, A Novel Approach for the Esthetic Rehabilitation of Edentulous Maxillary Anterior Alveolar Ridges: A Special Case File. *Prac Clin Invest* 2(1): 9-14.

preservation and immediate implant placement [3]. This procedure which forms a protective shield helps achieve periodontal ligament mediated ridge preservation. The socket-shield technique (SST) was first described by Hürzeler MB et al. [4] which consists of leaving a root fragment when extracting the tooth, specifically, the vestibular portion of the coronal third of the root. Socket shield principle states that root fragments intentionally retained in close proximity to or, in contact with the dental implants help to preserve or, promote the buccal and/or, proximal crestal alveolar bone.

CASE REPORT

The present case involves a male patient who reported to the Department with a chief complaint of grossly destructed teeth in upper front tooth region (Figure 1). The medical history was not conclusive. The patient was advised CBCT for diagnosis which revealed peri-apical lesion in relation to the endodontically treated tooth in the maxillary anterior region (Figure 2). The presence of peri-apical lesion was explained to the patient. After discussing the peri-apical lesion, esthetic consideration and need for immediate restoration of the lost teeth, the treatment mode decided was the placement of cortically engaged, smooth-surfaced implants using the so-recognized socket-shield technique (SST). Following the required steps, the palatal aspect of the tooth was carefully removed using a periosteal elevator (Figure 3A & Figure 3B). Slight elevation of the buccal and palatal flaps was performed to allow proper access for carrying-out curettage of the peri-apical lesions. Curettage was performed using curettes and rotary degranulation burs followed by a copious irrigation with Betadine and saline. Osteotomy was performed and a 2 mm drill was used to perforate the nasal floor. Nasal floor engagement provided rigid stabilization to the implant. The implant system used was BCES EX[®]. This implant system is designed to engage the fresh extraction sockets. It has a tapered design with smooth surface and active threads (Figure 4). Three implants were placed ensuring that they engage the nasal floor. Care was taken not to pressurize socket-shield during the placement of implants. Immediately after implant placement, impressions were made for the final prosthesis. According to the principles of immediate loading of the implants using smooth-surfaced implants with cortical engagement, a rigid splinting amongst the implants is advisable which was achieved in the present case by providing immediate final prosthesis using metal framework as a rigid splint (Figure 5). Rigid splinting of implants prevent micro-movement of the implants during the healing phases in an implant therapy. The soft tissues showed some degree of inflammation (Figure 6) on the day of cementation as they were manipulated during degranulation the peri-apical pathology. The patient was re-called after 1 week and then, after 1 and 6 months to evaluate the soft tissues as well as the occlusion. At the end of 6 months, the patient reported no discomfort and was satisfied with the esthetic outcome (Figure 7) of the entire procedure.

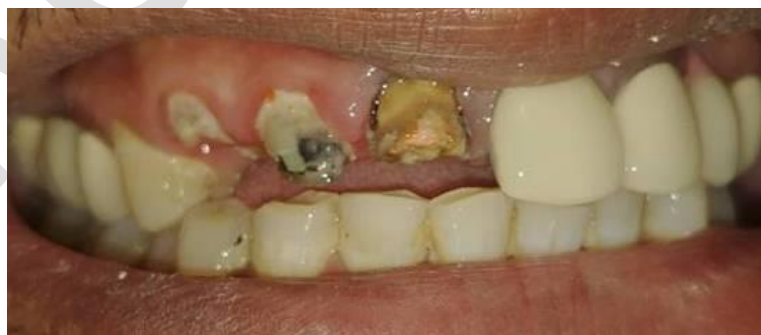

Figure 1: Grossly destructed teeth in maxillary anterior region.

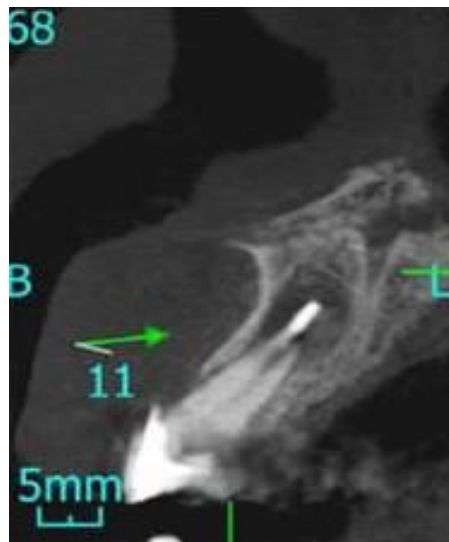


Figure 2: CBCT revealing peri-apical lesion in relation to the endodontically treated tooth in maxillary anterior region.

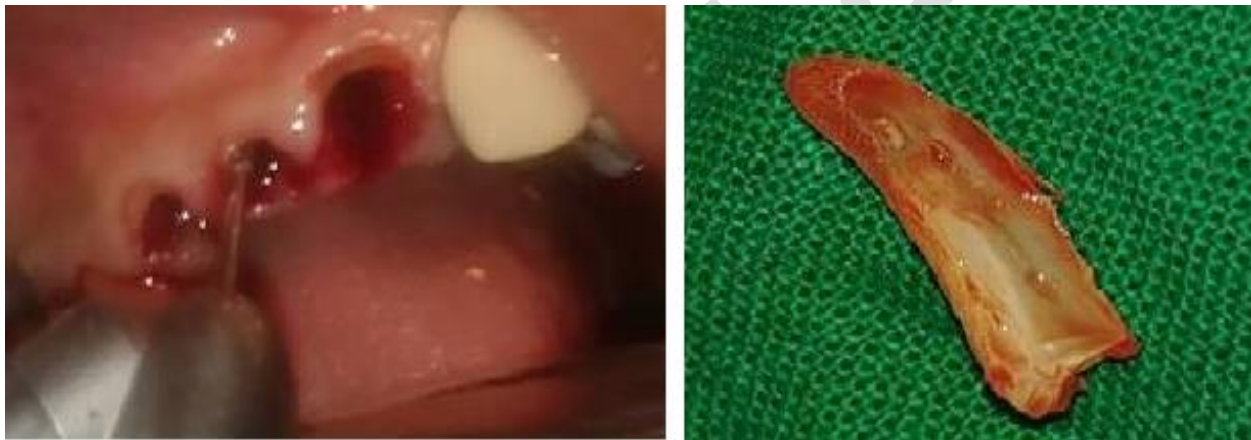

Figure 3A & Figure 3B: Palatal aspect of the tooth removed using a periotome.



Figure 4: BCES EX[®] implant system with a smooth surface implant revealing active threads for cortical engagement.

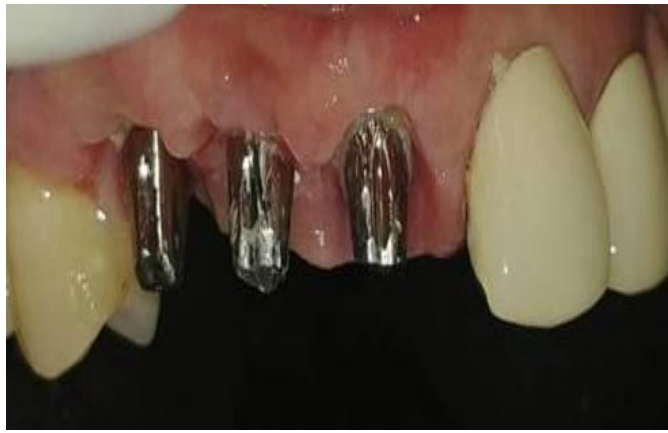

Figure 5: Immediate final prosthesis provided in the present case using metal framework as a rigid splint.

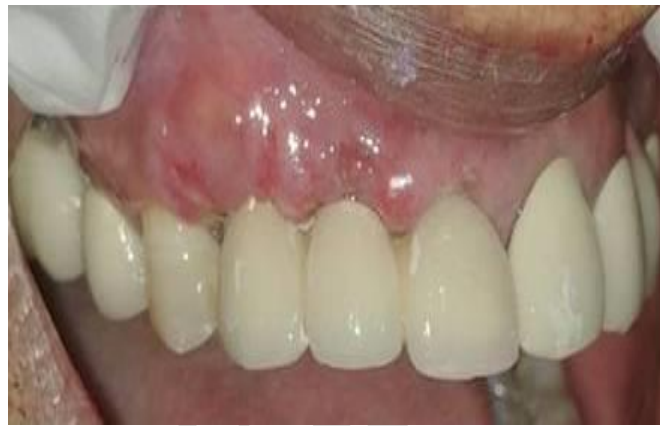

Figure 6: Inflamed soft tissues in the treated area due to surgical manipulation of the tissues.

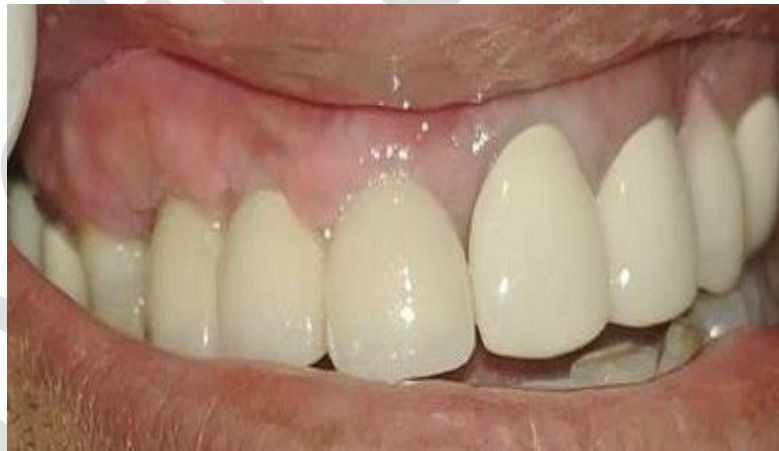

Figure 7: Successful clinical and esthetic outcome in the treated case as revealed on the follow-up visit of the patient after 6 months.

DISCUSSION

Socket shield technique has successfully demonstrated its potential to preserve the buccal tissues with predictable esthetic outcomes [4-6]. This approach helps eliminate the ridge contour changes associated with extraction and facilitates immediate implant placement. The literature, though, is devoid in this aspect with sufficient cases and studies done in this

regard emphasizing long term results, though, the ones published have shown promising results with high success rates [7-10]. The procedure involves a learning curve but can be mastered if the protocol is technically followed [11]. Other methods involving ridge preservation and maintenance involve the use of various biomaterials to obtain results, though, that, again, is highly unpredictable. Such techniques and procedures may, also, demand added surgical intervention which leads to inadvertent tissue manipulation and added post-surgical morbidities. The noted advantages of the so-called socket-shield technique lies in the fact that the use of biomaterials can be avoided which drastically reduces the cost and treatment times. This may, also, improve chances of patient's acceptance which was particularly observed in the present case [12]. The use of biomaterials, also, is not requisite and recommended in all cases as there is plethora of literature supporting evidence of successful clinical outcomes without the use of such materials [13]. The present case report, also, describes the successful use of socket shield technique with smooth-surfaced implants using nasal cortical engagement. The technique of cortical bone engagement has been well-documented in the literature. The implants used in this case were machined, smooth-surfaced implants with no surface roughness. Presence of such surface gives the operator the confidence that the implant will stay unaffected even if they are exposed to oral environment and/or, residual peri-apical infections. Unfortunately, with the use of conventional, surface-treated implants, year by year, the prevalence of peri-implantitis reported in the literature has increased alarmingly. The existing prevalence reported for such cases in case of surface-treated implants has been calculated between 11.3% and 47.1% [14]. Clinicians have successfully placed implants in the presence of peri-apical lesions, though, such conditions have been documented as the cause of retrograde infection on the implant surface [15]. The use of smooth-surfaced implants may prevent such a scenario as well as promote uneventful healing of the lesion post-implant placement [16]. Rigid splinting with the help of prosthesis along with cortical engagement permits the operator to immediately place and load these implants, though, the existing literature is almost lacking with very few attempts made using socket-shield technique along with immediate implant placements with the above mentioned design [17,18]. More cases along with long-term studies are, thus, mandated to collect evidence to support this type of treatment approach.

REFERENCES

1. Araújo MG, Lindhe J (2005) Dimensional ridge alterations following tooth extraction. An experimental study in the dog. *Journal of Clinical Periodontology* 32(2): 212-218.
2. Kan JY, Roe P, Rungcharassaeng K, et al. (2011) Classification of sagittal root position in relation to the anterior maxillary osseous housing for immediate implant placement: A cone beam computed tomography study. *International Journal of Oral & Maxillofacial Implants* 26(4): 873-876.
3. Du Toit J (2016) The pontic-shield: Partial extraction therapy for ridge preservation and pontic site development. *Periodontics* 36: 417-423.
4. Hürzeler MB, Zuhr O, Schupbach P, et al. (2010) The socket-shield technique: A proof-of-principle report. *Journal of Clinical Periodontology* 37(9): 855-862.
5. Bäumer D, Zuhr O, Rebele S, et al. (2015) The socket-shield technique: First histological, clinical, and volumetrical observations after separation of the buccal tooth segment - A pilot study. *Clinical Implant Dentistry and Related Research* 17(1): 71-82.
6. Glocker M, Attin T, Schmidlin P (2014) Ridge preservation with modified "socket-shield" technique: A methodological case series. *Dentistry Journal* 2(1): 11-21.
7. Mitsias ME, Siormpas KD, Kotsakis GA, et al. (2017) The root membrane technique: Human histologic evidence after five years of function. *BioMed Research International* 2017: 7269467.

8. Gluckman H, Salama M, Du Toit J (2018) A retrospective evaluation of 128 socket-shield cases in the esthetic zone and posterior sites: Partial extraction therapy with up to 4 years follow-up. *Clinical Implant Dentistry and Related Research* 20(2): 122-129.
9. Bramanti E, Norcia A, Cicciù M, et al. (2018) Postextraction dental implant in the aesthetic zone, socket shield technique versus conventional protocol. *Journal of Craniofacial Surgery* 29(4): 1037-1041.
10. Abadzhiev M, Nenkov P, Velcheva P (2014) Conventional immediate implant placement and immediate placement with socket-shield technique - which is better. *International Journal of Clinical Medicine Research* 1(5): 176-180.
11. Petsch M, Spies B, Kohal RJ (2017) Socket shield technique for implant placement in the esthetic zone: A case report. *International Journal of Periodontics & Restorative Dentistry* 37(6): 853-860.
12. Saeidi Pour R, Zuhr O, Hürzeler M, et al. (2017) Clinical benefits of the immediate implant socket shield technique. *Journal of Esthetic and Restorative Dentistry* 29(2): 93-101.
13. Siormpas KD, Mitsias ME, Kontsiotou-Siormpa E, et al. (2014) Immediate implant placement in the esthetic zone utilizing the “root-membrane” technique: Clinical results up to 5 years post loading. *International Journal of Oral & Maxillofacial Implants* 29(6): 1397-1405.
14. Koldslund OC, Scheie AA, Aass AM (2010) Prevalence of peri-implantitis related to severity of the disease with different degrees of bone loss. *Journal of Periodontology* 81(2): 231-238.
15. Ayangco L, Sheridan PJ (2001) Development and treatment of retrograde peri-implantitis involving a site with a history of failed endodontic and apicoectomy procedures: A series of reports. *International Journal of Oral & Maxillofacial Implants* 16(3): 412-417.
16. Baron M, Haas R, Dörtbudak O, et al. (2000) Experimentally induced peri-implantitis: A review of different treatment methods described in the literature. *International Journal of Oral & Maxillofacial Implants* 15(4): 533-544.
17. Lazarov A (2019) Immediate functional loading: Results for the concept of the strategic implant®. *Annals of Maxillofacial Surgery* 9(1): 78-88.
18. Ihde S, Ihde AA (2017) *Diagnostics and treatment plan for the work with the strategic implant®*. Munich: International Implant Foundation Publishing.