Clinical Surgery Journal

Case Report | Vol 3 Iss S1

Mesoappendix Hernia: An unusual Internal Hernia

Vinay HG[1], Ramesh Reddy G[2], Kiran Kumar[3]

Department of General Surgery, Vydehi institute of medical sciences and research centre, Whitefield, Bangalore - 560066 Karnataka, India

Correspondence should be addressed to Vinay H G, vinay_1771@yahoo.co.in

Received: January 17, 2020; Accepted: February 20, 2020; Published: February 28, 2020

ABSTRACT

Internal hernia is a rare cause of intestinal obstruction. Though different types of internal occur, herniation through the mesoappendix is reported only twice in the literature. We describe here such a type of hernia which could be diagnosed only on laparotomy. There are no specific symptoms and signs other than those of intestinal obstruction, hence differential diagnosis of internal hernia should always be kept in mind while opening the abdomen.

KEYWORDS

Hernia; Obstruction; Mesoappendix; Laparotomy

1. INTRODUCTION

Intestinal obstruction caused by internal hernia is rare, with an incidence of between 0.2% and 0.9% [1]. Diverse types of internal hernias occur based on location; hernias can be paraduodenal, pericecal, Winslow's foramen, trans-mesenteric, pelvic, inter-sigmoid, and supravesical and rarely omental hernias [2]. Generally hernias develop from a congenital anatomical opening such as foramen of Winslow or due to malrotation of the bowel. Iatrogenic due to post surgical causes especially after Roux-En-Y reconstruction are also increasing in incidence. Hernias through mesenteric defects are the least common of intra-abdominal hernias [3]. Here, we present a 55-year-old patient who presented with intestinal obstruction due to herniation of the small bowel through mesoappendix.

2. CASE REPORT

A 55-year-old male patient presented with acute onset of pain abdomen of 3 days duration, associated with bilious vomiting and constipation. On examination, patient was dehydrated with tachycardia. Abdomen was distended with no signs of peritonitis, bowels sounds were absent and per rectum was empty.

Abdominal radiography was performed which revealed multiple air fluid levels in small bowl, were as colonic distension was absent suggestive of small bowel obstruction. Computed tomography (CT) of the abdomen was done mainly to localize the site of obstruction and to rule out malignancy. CT (Figure 1) revealed obstruction at the level of terminal ileum in the right lower abdomen, and nothing more helpful.

Patient was taken for emergency Laparotomy with a midline incision. The findings consisted of strangulated distal ileum through a rent in the mesoappendix with congestion of the herniated bowel loop (Figure 2 & Figure 3). Mesoappendix was transected, and appendicectomy was done. The bowel motility and

Citation: Vinay HG, Mesoappendix Hernia: An unusual Internal Hernia. Clin Surg J 3(S1): 11-13.

© 2020 The Authors. Published by TRIDHA Scholars.

perfusion recovered once the hernia was reduced (Figure 3). Post-operative recovery was uneventful. Patient was started on oral feeds on POD2 and discharged on POD6.

Figure 1: CT abdomen showing dilated small bowels upto terminal ileum.

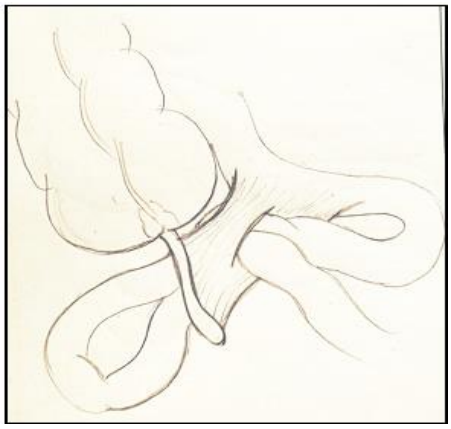

Figure 2: Schematic representation of the internal herniation.

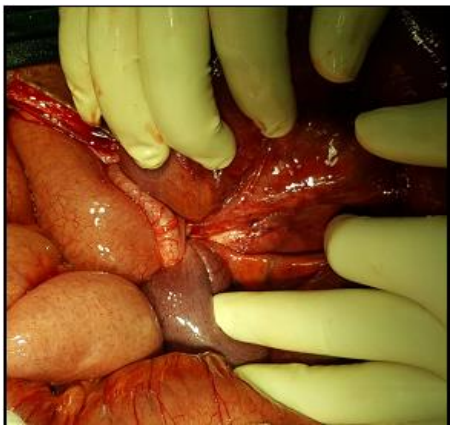

Figure 3: Intra-operative photograph showing the herniation of distal ileum with congestion.

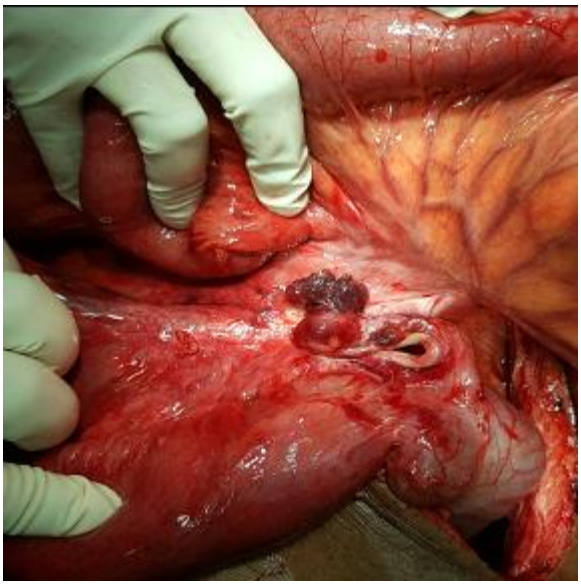

Figure 4: Intra-operative photograph after release of the herniation with rent in mesoappendix.

3. DISCUSSION

Intestinal obstruction is a common cause of acute abdomen which results in high mortality unless managed appropriately. Preoperative diagnosis of intestinal obstruction based on physical examination with no previous history of abdominal surgery is difficult. Common causes of intestinal obstruction such as colorectal cancer, intussusceptions, volvulus and adhesions can be diagnosed with good imaging studies preoperatively. However, preoperative diagnosis of internal hernia may be misleading, unless a good radiologist can report a CT abdomen [1,4].

The types of trans-mesenteric hernias include (a) trans-mesocolic due to defects of the small intestine's mesentery, and (b) Peterson's hernia, a defect through the transverse mesocolon. Among adults the main causes of internal hernias are previous gastrointestinal surgery, abdominal trauma or intraperitoneal inflammation [1,5,6].

The cause of trans-mesoappendicular internal hernia was unknown. Congenital defect in the mesoappendix could have been the cause of the internal, though it is very unusual in the elderly [5,6]. The clinical detection of

internal hernia is difficult as symptomatology is unspecific. In this case the cause of obstruction was unknown, and further necessitated a laparotomy.

After thorough reviewing of literature only two case reports of transmesoappendicular hernia have been reported. James et al in the year 1963 reported a single case of herniation through mesoappendix in a 80-year-old female [7] and Barman et al published a report of herniation of meckel's diverticulum in the mesoappendix in a 5 month old infant [8].

Even though CT scan is the gold standard to diagnose internal hernia, it has a specificity of 76% and sensitivity of 63% only [1]. Visible signs in CT scan may include displacement of the mesenteric trunk towards the hernia, elongation, grouping and engorgement of mesenteric vessels, abnormal encapsulation of intestinal loops in the peritoneal cavity, stasis and absence of intraluminal contrast progression [1,5,6].

4. CONCLUSION

We report a case of internal hernia through the meso appendix, which is very rare. Pre-operative diagnosis is seldom made. It has to be managed like any other case of intestinal obstruction, either by laparoscopy or laparotomy and appendicectomy.

5. ACKNOWLEGEMENT

Financial support is nil and there is no conflict of interest.

REFERENCES

1. Blachar, M P Federle, S. Forrest Dodson (2001) Internal hernia: Clinical and imaging findings in 17 patients with emphasis on CT criteria. Radiology 218(1): 68–74
2. Hashimoto D, Hirota M, Sakata K, et al. (2012) Adult transmesenteric hernia: Report of two cases. Surgery Today 42(5): 489-492.
3. Cutler GD (1925) Mesenteric Defects as Cause of Intestinal Obstruction. The Boston Medical and Surgical Journal 192(7): 305-311.
4. Lubat E, Gordon RB, Birnbaum BA, et al. (1990) CT diagnosis of posterior perineal hernia. American Journal of Roentgenology 154: 761-762
5. Mathie D, Luciani A (2004) Internal abdominal herniations. American Journal of Roentgenology 183(2): 397–404.
6. Zissin R, Hertz M, Gayer G, et al. (2005) Congenital internal hernia as a cause of small bowel obstruction: CT findings in 11 adults patients. British Journal of Radiology 78(933): 796–802.
7. Rooney JA, Caroll JP, Keeley JL (1963) Internal hernias due to defects in the meso-appendix and mesentry of small bowel and probable Ivemark syndrome: Report of two cases. Annals of Surgery 157(2): 254-258.
8. Barman S, Md. Hadiuzzaman, Ray S, et al. (2016) Internal herniation of Meckel's diverticulum through meso appendix in infant: An extremely rare occurrence. CHRISMED Journal of Health and Research 3(1): 89-91.