

Mammary Myofibroblastoma in a Male Patient

Eslam Youssef^{1,4*}, Xiaochen Liu¹, RaeLynne MacBeth⁴, Mazzin Elsamaloty³, Dalia Ibrahim² and Haitham Elsamaloty¹

¹Radiology Department, The University of Toledo Medical Center, Toledo, OH, USA

²Pathology Department, The University of Toledo Medical Center, Toledo, OH, USA

³The University of Toledo College of Medicine, Toledo, OH, USA

⁴Diagnostic and Radiology Department, Cairo University Hospitals, Cairo, Egypt

*Corresponding author: Eslam Youssef, The University of Toledo Medical Center, 3000 Arlington Ave., Toledo, Ohio 43614-2598, USA, Tel: (419) 383-3936; E-mail: eslam.youssef@utoledo.edu

Abstract

A mammary myofibroblastoma is a rare benign lesion found within the breast tissue of both males and females. Although it is a benign mass, it may mimic breast carcinoma on mammography and sonographic imaging. This is a case report of a 68-year-old male with a history of prostate cancer presenting with a tender and palpable mass of the left breast in the 11 o'clock position. Ultrasound-guided core biopsy was performed and pathology confirmed the diagnosis of myofibroblastoma of the breast.

Mammary myofibroblastoma should be considered in a patient presenting with a breast mass, particularly older men and postmenopausal women. A core biopsy should be obtained to rule out a more serious diagnosis.

Keywords: *Myofibroblastoma; Male; Case report*

Received Date: October 22, 2018; **Accepted Date:** November 03, 2018; **Published Date:** November 10, 2018

Introduction

Myofibroblastomas are uncommon, benign stromal tumors of the breast first described in 1987 by Wargotz et al. [1]. Myofibroblastomas are pathologically described as a 'benign spindle cell tumor of the mammary stroma' due to its derivation from stromal myofibroblasts commonly found in the breast parenchyma [2]. Genetically, it is thought to be correlated with the deletion of the 13q14 region, similar to other types of benign mesenchymal and stromal neoplasms [2,3]. Myofibroblastomas typically occur in older men and postmenopausal women, however, they can present at any age [4]. Although myofibroblastomas are most commonly found within the breast, there have been extramammary locations reported in the literature as well [5-8].

Here is a case report of a myofibroblastoma of the breast in a patient with prostate cancer

Case History

Citation: Eslam Youssef, Mammary Myofibroblastoma in a Male Patient. J Clin Cases Rep 2(1): 17-20. DOI: <https://doi.org/10.46619/joccr.2019.2-1031>
© 2019 Tridha Scholars.

A 68-year-old male presented with a tender, palpable mass of the left breast in the 11 o'clock position which had been present for 3 months. The patient had a history of prostate cancer, raising the concern for metastatic carcinoma as a differential diagnosis. The patient underwent a diagnostic bilateral mammogram which showed scattered calcifications and a mass with macrolobulated margins measuring 2.3 cm × 1.2 cm × 2.0 cm. Ultrasound-guided core biopsy of the left breast mass was performed and revealed myofibroblastoma of the breast.

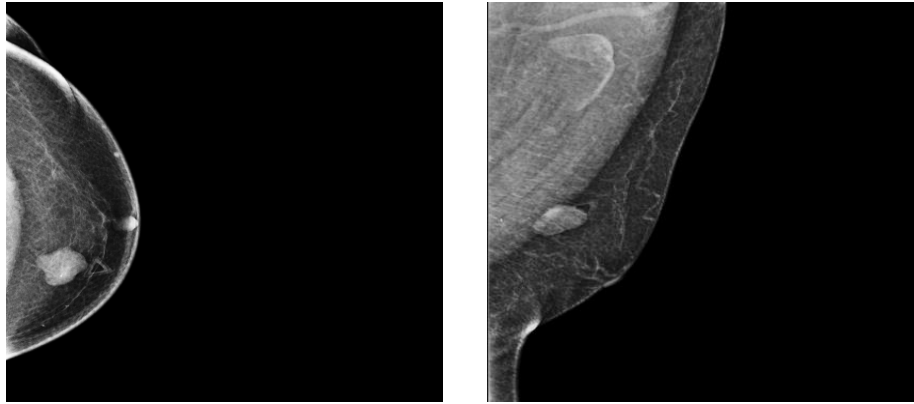


Figure 1: Cranio-Caudal (CC) and Mediolateral Oblique (MLO) diagnostic mammogram views obtained and shows a high-density lesion within the 11 o'clock position of left breast with macrolobulated margins.

Diagnostic mammogram revealed a high-density lesion with macrolobulated margins at the 11 o'clock position in the left breast without spiculated borders (Figure 1). Scattered calcifications were visualized within the left breast. It was classified as BI-RADS 4 (suspicious finding) and ultrasound-guided biopsy was recommended.

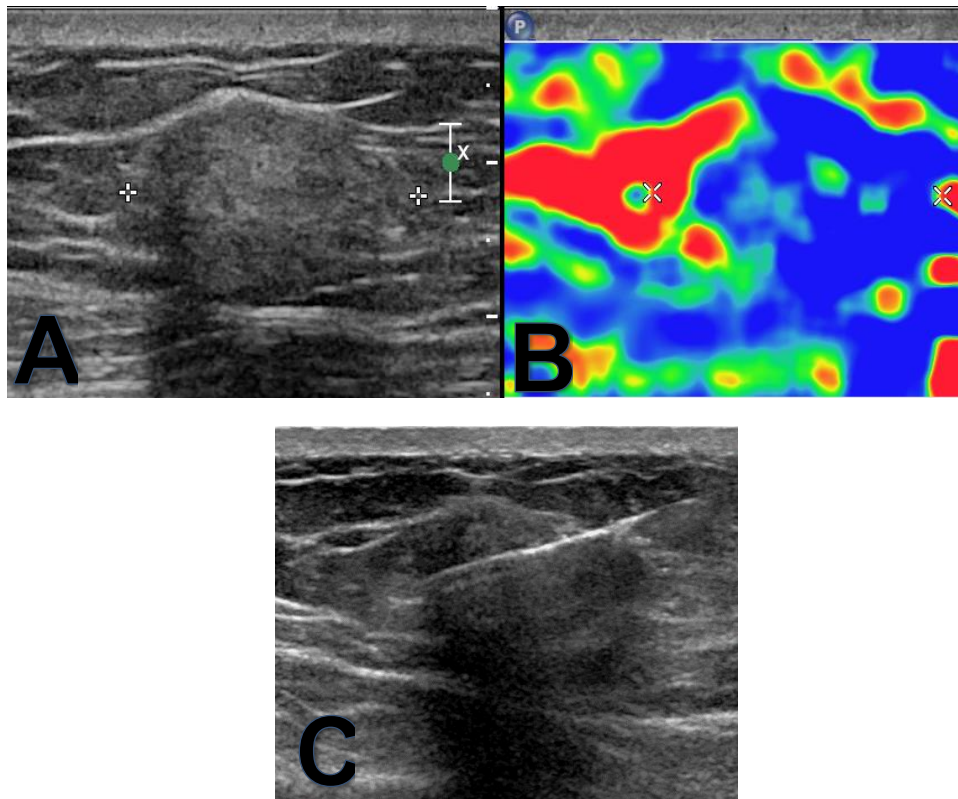


Figure 2: Grey scale ultrasound and elastography (Image A&B) in the area of palpable abnormality in the left breast show an elongated hyperechoic smoothly margined mass parallel to the tissue planes that measures 2.3 cm × 1.2 cm × 2.0 cm. There are areas that are hard and areas that are soft by elastography. Ultrasound guided biopsy (Image C) using 14-gauge, coaxial biopsy gun, access into the hyperechoic mass was achieved and 4 core biopsy samples were obtained.

Focused ultrasound demonstrated an elongated hyperechoic mass with smooth margins measuring 2.3 cm × 1.2 cm × 2.0 cm. There was minimally increased color flow internally. Elastography showed both hard and soft areas within the mass (Figure 2 and Figure 3).

Ultrasound-guided biopsy was performed using a 14-gauge coaxial biopsy gun and 4 core biopsy samples were obtained. Pathology results classified the mass as a myofibroblastoma of the breast. Patient was diagnosed with myofibroblastoma of the breast.

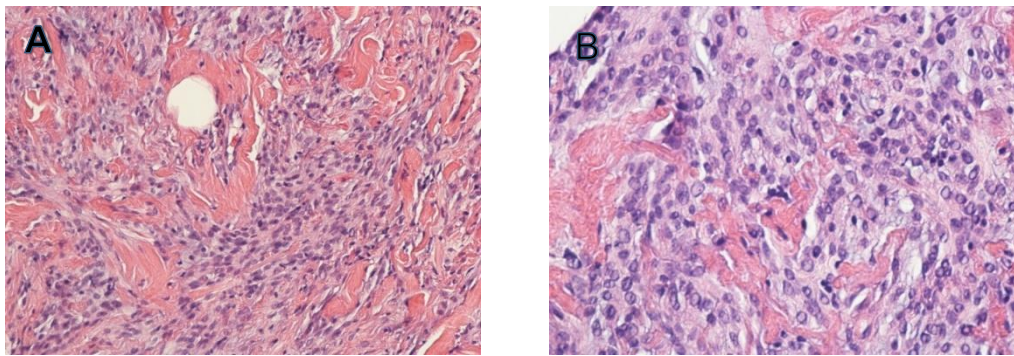


Figure 3: (A) Low power image showing tumor cells with characteristic spindle cell pattern dispersed amongst thick bundles of collagen and devoid of breast parenchyma (Hematoxylin and Eosin X 20) (B) High power image showing bland spindle cells with minimal mitotic figures dispersed among collagen bundles (Hematoxylin and Eosin X 40)

Discussion

Mammary myofibroblastoma is a rare, benign neoplasm that commonly presents as a single, freely-moveable, palpable mass upon examination. These masses are typically unilateral, painless, and have the ability to slowly increase in size. The average size is between 1 cm and 4 cm; however, much larger dimensions have been reported in the literature [9].

Myofibroblastomas occur in both sexes and are most common during the ages of 40 to 87-years-old. Older men and postmenopausal women tend to be affected more often [4]. Myofibroblastomas are most commonly found within the breast tissue, but they have also been identified in other areas of the body as well. Although they are less common, there have been case reports identifying extramammary myofibroblastomas in the abdominal wall, thigh, and even tongue [3,4,7].

Mammographically, myofibroblastomas present as a well-circumscribed mass without architectural distortion or suspicious calcifications [4]. They may also demonstrate microlobulated margins which can mimic breast carcinoma on mammography [10]. In the presented case, mammography showed the presence of scattered calcifications and a dense mass with macrolobulated margins in the affected breast. Sonographically, there have been cases where a myofibroblastoma appears as a circumscribed slightly echogenic lesion with distal acoustic attenuation, as well as a circumscribed, slightly hypoechoic and non-attenuating lesion [4]. Its sonographic appearance may reveal ill-defined borders along with posterior shadowing, and a biopsy is recommended to distinguish it from other possible differentials [11].

Possible differentials for a mass in the male breast include, but are not limited to, primary breast carcinoma, fibroadenoma, gynecomastia, and more importantly in the case presented, metastatic carcinoma due to his personal history of prostate cancer.

Surgical excision is recommended, although the physician may opt to follow it using ultrasound and/or mammography every six months up to two years in order to confirm stability [12]. There have been no reports of malignant transformation and it is unlikely for myofibroblastomas to recur after surgical excision, likely due to their smooth margins.

Conclusion

Myofibroblastoma of the breast is a rare, benign mass that is difficult to distinguish from other differentials such as a benign fibroadenoma or carcinoma. It's more common in old males and postmenopausal females. It's appearance on mammography and ultrasound are inconclusive, and a core biopsy tissue sample is needed to confirm this benign finding. Surgical excision is recommended, however, there have been no reports of malignant transformation. Therefore, follow-up studies may be performed to confirm stability for two years.

References

1. Wargotz ES, Weiss SW, Norris HJ (1987) Myofibroblastoma of the breast. Sixteen cases of a distinctive benign mesenchymal tumor. *The American Journal of Surgical Pathology* 11(7): 493-502.
2. Comer JD, Cui X, Eisen CS, et al. (2017) Myofibroblastoma of the male breast: a rare entity with radiologic-pathologic correlation. *Clinical Imaging* 42: 109-112.
3. Metry M, Shaaban M, Youssef M, et al. (2016) Myofibroblastoma of the breast: literature review and case Report. *Case Reports in Oncological Medicine* 1714382.
4. Greenberg JS, Kaplan SS, Grady C (1998) Myofibroblastoma of the breast in women: imaging appearances. *American Journal of Roentgenology* 171(1): 71-72.
5. Pan J, Wang S, Zhang Y, et al. (2016) Mammary myofibroblastoma in the right lateral abdominal wall. *World Journal of Surgical Oncology* 14: 55.
6. Abdul-Ghafar J, Ud Din N, Ahmad Z, et al. (2015) Mammary-type myofibroblastoma of the right thigh: a case report and review of the literature. *Journal of Medical Case Reports* 9: 126.
7. Sahin AA, Ro JY, Ordonez NG, et al. (1990) Myofibroblastoma of the tongue. An immunohistochemical, ultrastructural, and flow cytometric study. *American Journal of Clinical Pathology* 94(6): 773-777.
8. Zahid MF, Zafar I, Din NU, et al. (2015) Mammary myofibroblastoma: a clinico- pathologic study of six cases. *Breast Disease*. 35(2): 143-148.
9. Omar LA, Rojanapremsuk T, Saluja K, et al. (2016) Radiologic and histologic presentation of male mammary myofibroblastoma. *Proceeding (Baylor University Medical Center)* 29(3): 321-322.
10. Rochlis E, Germaine P (2017) Radiologic presentation of a myofibroblastoma of the adult male breast. *Radiology Case Reports* 12(3): 439-442.
11. Dockery WD, Singh HR, Wilentz RE (2001) Myofibroblastoma of the male breast: imaging appearance and ultrasound-guided core biopsy diagnosis. *The Breast Journal* 7(3): 192-194.
12. Mele M, Jensen V, Wronecki A, Lelkaitis G (2011) Myofibroblastoma of the breast: Case report and literature review. *International Journal of Surgery Case Reports* 2(6): 93-96.