

Haemophilus Parainfluenzae - A Rare Organism to Cause Endocarditis in a Healthy Individual without Predisposing Factors: A Case Report

Masood Ghori^{1*}, Muhanad Alkasser¹ and Mustafa Alkasser²

¹Cardiac Science Department, Sheikh Khalifa Medical City, Abu Dhabi, United Arab Emirates

²Internal Medicine Department, Sheikh Khalifa Medical City, Abu Dhabi, United Arab Emirates

Correspondence should be addressed to Masood Ayyub Ghori, masood_ghori@hotmail.com

Received Date: August 12, 2020; **Accepted Date:** August 25, 2020; **Published Date:** September 01, 2020

ABSTRACT

Haemophilus parainfluenzae (*H. parainfluenzae*) endocarditis is a rare condition, even more unusual if encountered in a patient who has no history of structural heart disease or prior oral surgery. We describe a 29-years old male patient admitted with fever, cough and general malaise for three weeks, worsening dyspnea of one day, a pan-systolic murmur at the cardiac apex and signs of heart failure. Cardiac ultrasound revealed a 19 mm × 6 mm vegetation attached to the anterior mitral leaflet and severe mitral regurgitation. A diagnosis of infective endocarditis (IE) was employed. The patient underwent early vegetectomy and mitral valve repair. Blood cultures drawn on admission grew *H. parainfluenzae* treated with six-weeks of ceftriaxone. To the best of our knowledge, *H. parainfluenzae* endocarditis in a patient without predisposing factors is extremely scarce in literature. Owing to the rare encounter of this organism in infective endocarditis in healthy adults, presentation of this case and cited literature might be of interest for cardiologists, cardiac surgeons and infectious disease specialist.

KEYWORDS

Haemophilus parainfluenzae (*H. parainfluenzae*); Infective endocarditis (IE)

INTRODUCTION

H. parainfluenzae is a gram-negative coccobacillus that is found in the normal flora of the mouth. It is an uncommon cause of IE, usually affecting immunocompromised hosts, intravenous drug users or patients with poor oral hygiene and pre-existing valvular lesions.

We report a complicated case of *H. parainfluenzae* endocarditis and its management with mitral valve repair during active phase of the disease followed by

antimicrobial therapy in a patient with no known predisposing factor.

CASE REPORT

A 29-years old man with no significant past medical history, presented with a new onset dyspnea that began on the morning of admission, preceded by a 3-weeks history of low-grade fevers, chills, fatigue and 8-kilogram weight loss. On examination, he was in moderate respiratory distress with a respiratory rate of 24 breath per minute, tympanic temperature of 36.9°C, ambient oxygen

Citation: Masood Ghori, *Haemophilus Parainfluenzae* - A Rare Organism to Cause Endocarditis in a Healthy Individual without Predisposing Factors: A Case Report. J Heart 2(1): 23-26.

saturation of 92 percent and right jugular venous pressure of 10 cm of H₂O above the manubrium with no ankle or sacral pitting edema. His radial pulse was 125 beat per minute and brachial blood pressure measured 110/63 mm Hg. Cardiopulmonary auscultation revealed signs of left

heart failure and a Levine grade-IV systolic murmur maximally audible at the apex radiating to the back, consistent with mitral regurgitation. Initial laboratory results summarized in (Table 1).

Laboratory Data	Values	Normal Values	Laboratory Data	Values	Normal Values
White blood cell count	8.7 × 10 ⁹ /L	4.5-11 ⁹ /L	Serum creatinine	59 micromol/L	62-106 micromol/L
Hemoglobin	82 g/L	132-173 g/L	Urea	3.20 mmol/L	2.80-8.10 mmol/L
Platelets	337 × 10 ⁹ /L	140-400 × 10 ⁹ /L	CRP	131.88 mg/L	<5 mg/L
NT-pro BNP ng/L	470	0.0-85.8	Procalcitonin	0.02 ng/ml	0.50 ng/ml

Table 1: Laboratory results.

Transthoracic echocardiogram (using Philips EPIQ 7 Ultrasound System, WA, USA) revealed a 19 mm × 6 mm, highly mobile echogenic mass attached to Anterior Mitral Leaflet (Figure 1) and Carpentier type II severe eccentric mitral regurgitation (Figure 2).

mitral annulus. Blood cultures drawn on admission revealed Gram-negative bacilli, identified as *H. parainfluenzae*, sensitive to multiple drugs (Table 2).

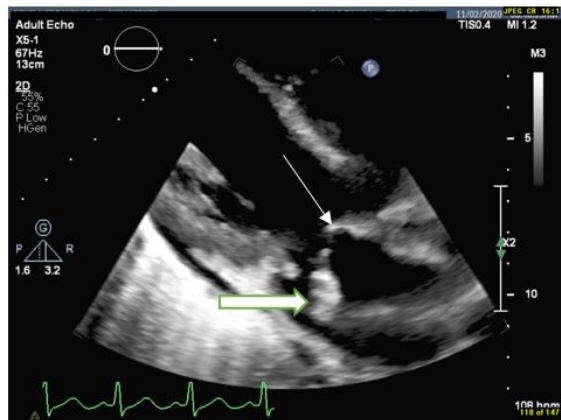


Figure 1: Transthoracic parasternal view depicting anterior mitral leaflet (thin white arrow) and large vegetation attached to it (thick white arrow).

Using Duke’s modified criteria, these findings were felt to be most consistent with a diagnosis of IE and an empiric treatment with ceftriaxone and vancomycin following three sets of blood cultures that were drawn 1 hour apart. Owing to large size vegetation and mitral leaflet destruction leading to severe mitral regurgitation and heart failure, the patient was transferred to another facility where he underwent early vegetectomy, anterior mitral leaflet repair and pericardial patch reconstruction of the

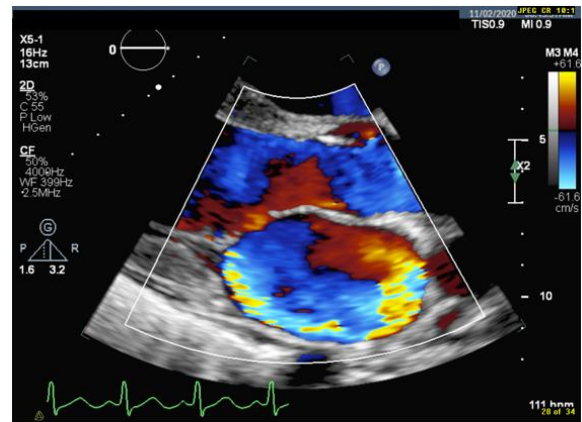


Figure 2: Transthoracic echocardiograph: Color Doppler image showing posteriorly directed eccentric mitral regurgitation of severe intensity by visual assessment.

	<i>Haemophilus parainfluenzae</i>		<i>Haemophilus parainfluenzae</i>
Drug	KB Interp	Drug	KB Interp
Amoxicillin/Clavulanate	S	Cefuroxime	S
Ampicillin	S	Ciprofloxacin	S
Azithromycin	S	Tetracycline	S
Ceftriaxone	S	Trimethoprim/Sulfa	S

Table 2: Blood culture results and sensitivity report.

With a postoperative six-week course of ceftriaxone 2 gram intravenously daily, the patient progressively convalesced from sepsis, operative morbidity and other constitutional symptoms.

Pre-discharged blood cultures and transthoracic echocardiogram revealed complete eradication of

bacteremia and a competent mitral valve with no remnants of the vegetation (Figure 3) respectively.

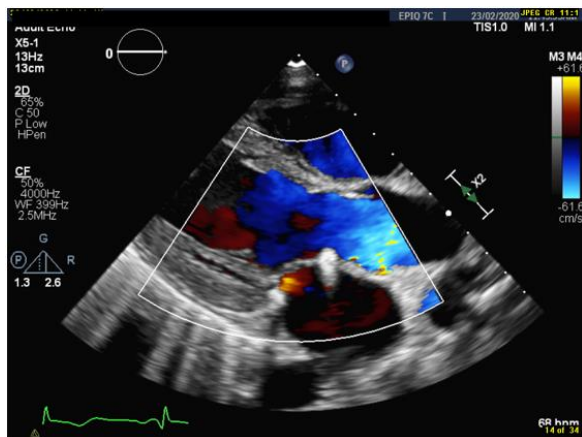


Figure 3: Transthoracic echo image indicating competent post-repaired mitral valve.

The patient was discharged on acetylsalicylic acid 75 mg daily, metoprolol 25 mg bid. At follow-up two months later, he was doing well without any signs or symptoms of heart failure. Repeat TTE showed no remnants of vegetations and a competent mitral valve.

DISCUSSION

H. parainfluenzae, an indigenous agent of oropharynx in healthy individuals, is a Gram-negative bacterium that belongs to the HACEK (*H. aphrophilus*, *Actinobacillus actinomycetemcomitans*, *Cardiobacterium hominis*, *Eikenella corrodens* and *Kingella kingae*) group of the organisms. It accounts for 0.5% - 1% of all cases of IE [1], usually affecting patients with poor oral hygiene, pre-existing valvular lesions, immunocompromised hosts and intravenous drug users. Typical clinical pattern of *H. parainfluenzae* endocarditis is sub-acute, developing after dental procedures in patients with preexisting valvular disease [2,3], classically with a large size vegetation, portending high risk for peripheral embolization and stroke [4]. *H. parainfluenzae* endocarditis complicated with heart failure in a patient without any predisposing or precipitating factors, as in our case, is extremely rare [5].

In cases of infective endocarditis complicated with valve disruption and heart failure, the mortality without early surgical intervention is high. European Society of Cardiology, American Heart Association and American Association for Thoracic Surgery recommend early surgery as class-I indication if a patient has a large size vegetation, develops valve dysfunction or heart failure [6-8]. Concordantly, we referred our patient for early surgical intervention as he manifested with heart failure secondary to mitral valve dysfunction and a large size vegetation.

The advantages of mitral valve repair over replacement is well documented [9]. Our patient underwent vegetectomy, anterior mitral leaflet repair and pericardial patch reconstruction of the mitral annulus with an excellent outcome.

Treatment of HACEK endocarditis relies on third-generation cephalosporin with a favorable outcome in 80% - 90% of cases, with or without cardiac surgery [10]. Accordingly, we treated our patient with ceftriaxone for six weeks. He gradually convalesced from sepsis, operative morbidity and another constitutional symptom. Repeat blood cultures and transthoracic echocardiogram, respectively, revealed complete eradication of bacteremia and competent mitral valve with no remnants of vegetation. The patient was discharged in a stable condition, on acetylsalicylic acid 75 mg daily, metoprolol 25 mg bid. At follow-up two months later, he was doing well without any signs or symptoms of heart failure.

LIMITATION

As the patient underwent surgery in another facility, the authors couldn't get macroscopic description of the valve, to confirm whether it was a normal mitral valve or had pre-existing but clinically silent disease that predisposed the patient for endocardial infection.

CONCLUSION

We report a complicated case of endocarditis by *H. parainfluenzae*, a rare organism in endocarditis in a non-addict, immunocompetent patient with no prior history of structural heart disease or oro-dental surgery. Sharing knowledge through this case and cited literature about such a rarely encountered causative agent in endocarditis might enhance our understanding about such condition and its management.

ACKNOWLEDGMENT

The authors acknowledge efforts of Fatima Masood, MBBS final-year student, for her contribution in writing this manuscript.

CONFLICT OF INTEREST

The authors declare that there is no conflict of interests regarding the publication of this paper and have not received any funding from any source for this case report.

REFERENCES

1. Ryu KH, Choi HJ, Park SH, et al. (2003) Two Cases of *Haemophilus parainfluenzae* endocarditis. Infection and Chemotherapy 35(5): 345-349.
2. Brouqui P, Raoult D (2001) Endocarditis due to rare and fastidious bacteria. Clinical Microbiology Reviews 14(1): 177-207.
3. Darras-Joly C, Lortholary O, Mainardi JL, et al. (1997) *Haemophilus endocarditis*: Report of 42 cases in adults and review. Clinical Infectious Diseases 24(6): 1087-1094.
4. Chambers ST, Murdoch D, Morris A, et al. (2013) HACEK infective endocarditis: Characteristics and outcomes from a large, multi-national cohort. PLoS One 8(5): e63181.
5. Miyazaki T, Akashi F, Shinzato K, et al. (1985) A case of infective endocarditis due to *Haemophilus parainfluenzae*. Kansenshogaku zasshi. The Journal of the Japanese Association for Infectious Diseases 59(10): 1017.
6. Habib G, Hoen B, Tornos P, et al. (2009) Guidelines on the prevention, diagnosis, and treatment of infective endocarditis (new version 2009): The task force on the prevention, diagnosis, and treatment of infective endocarditis of the European Society of Cardiology (ESC). European Heart Journal 30(19): 2369-2413.
7. Baddour LM, Wilson WR, Bayer AS, et al. (2015) Infective endocarditis in adults: Diagnosis, antimicrobial therapy, and management of complications: A scientific statement for healthcare professionals from the American Heart Association. Circulation 132(15): 1435-1486.
8. Pettersson GB, Coselli JS, Hussain ST, et al. (2017) American Association for Thoracic Surgery (AATS) Consensus guidelines: Surgical treatment of infective endocarditis. The Journal of Thoracic and Cardiovascular Surgery 153: 1241-1258.
9. Ambrosioni J, Martinez-Garcia C, Llopis J, et al. (2018) HACEK infective endocarditis: Epidemiology, clinical features, and outcome: A case-control study. International Journal of Infectious Diseases 76: 120-125.
10. Revest M, Egmann G, Cattoir V, et al. (2016) HACEK endocarditis: State-of-the-art. Expert Review of Anti-Infective Therapy 14(5): 523-530.