

Bifid Mandibular Canals - A Case Report and Mini Review

Sourav Sarkar* and Saini Mondal

Department of Dentistry, Sri Ramkrishna Institute of Medical Sciences and Sanaka Hospitals, West Bengal, India

Correspondence should be addressed to Sourav Sarkar, E-mail: sourav_allen9927@yahoo.in

Received March 27, 2020; Accepted April 28, 2020, Published May 4, 2020

ABSTRACT

Although the mandibular canal is considered as a single bilateral structure, there are several reports in the literature which gives evidence of a second or even a third accessory mandibular canal. Bifid mandibular canals may originate from the mandibular foramen independently or might bifurcate from a single canal during its course inside the mandible. This report describes a case of a bilateral Bifid mandibular canal suspected by a panoramic radiograph and confirmed by a CBCT prior to a dental treatment.

Keywords: Bifid mandibular canal; Inferior alveolar nerve; CBCT; Orthopantomogram; Mandible

1. INTRODUCTION

The presence of bifid mandibular canals is an unusual but not rare occurrence. The mandibular canal containing the inferior alveolar artery, vein, and nerve, originates from the mandibular foramen and terminates at mental foramen [1-4]. In radiology, mandibular canal's appearance has been described as "a radiolucent dark ribbon between two white lines" [5]. White and Pharoah defined it as "dark linear shadow with thin radiopaque superior and inferior borders cast by the lamella of bone that bounds the canal" [6]. Understanding of its anatomic variations is very important due to its clinical implications in various oral and maxillofacial treatments like removal of wisdom teeth [7], mandibular implant placement [8], in bilateral sagittal split osteotomy procedures and during fixation of mandibular fractures.

Bifid mandibular canals may originate from the mandibular foramen independently or might bifurcate from a single canal during its course inside the mandible.

Bifid mandibular canals have been by classified by multiple authors according to anatomical location and configuration, on panoramic radiographs and computerized tomography. According to Carter and Keen [1] inferior alveolar nerve can be arranged as - Type I: single large bony canal, Type II: canal is lower down in the mandible and Type III: canal separates posteriorly into two large branches.

Nortje et al. [9] gave patterns of duplication as - Type I: duplicate canals from a single mandibular foramen which can be of same size/ lower canal smaller/ upper canal smaller. Type II: short upper canal up to the second molar areas. Type III: two canals from separate foramina, joining at molar area and Type IV: supplemental canals

Citation: Sourav Sarkar, Bifid Mandibular Canals- A Case Report and Mini Review. Case Rep Dent Sci 1(1): 5-8.

CRDS/© 2020 The Authors. Published by TRIDHA Scholars.

joining the main canals in the retromolar areas. This report describes a case of a bilateral Bifid Mandibular Canal suspected by a panoramic radiograph and confirmed by a CBCT prior to a dental treatment.

2. CASE REPORT

A 43-years-old female patient reported to the Department of Dentistry, with a complaint of missing teeth for 6 months and wanted to get them replaced with dental implant rehabilitation. Intraoral examination revealed multiple missing teeth. The patient mentioned a history of difficulty in anesthetizing her lower left first molar during extraction by her previous dentist. The patient was advised for an orthopantomogram for further evaluation. Orthopantomogram revealed an edentulous area at 36 region and also the existence of bilateral bifid mandibular canal was noticed. In her left jaw two separate canals with well-corticated wall could be seen.

A CBCT was requested for further assessment. The axial and coronal cross sections revealed two mandibular canals ending into one single mental foramen and in the right side the lowest branch of the canal showed no relation with the apical part of the roots of the molars whereas the upper branch was positioned lingual to the roots a sign of high risk for nerve damage. The patient was informed about the reason of previous difficult local anesthesia due to the presence of this anatomical aberration.

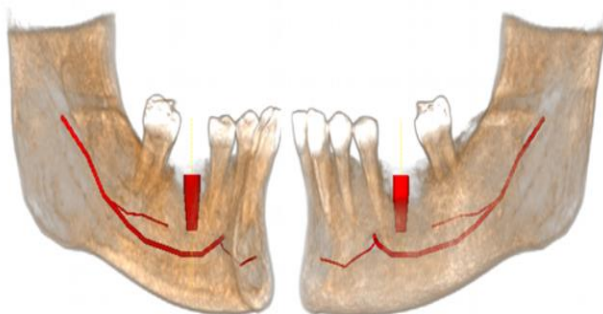


Figure 1: Presence of bifid inferior alveolar nerve bilaterally, dividing from the main trunk below the lower second molar region.

3. DISCUSSION

It is common to misinterpret a bifid mandibular canal in an orthopantomogram due to superimposition of various anatomical structures and inadequate positioning of the patient [10]. Although, the mandibular canal is considered as a single bilateral structure, there are several reports in the literature which gives evidence of a second or even a third accessory mandibular canal [11-26]. Pioneer studies reported the incidence of bifid mandibular canals as 1% [9,10]. These study models evaluated the presence of bifid mandibular canals using orthopantomogram. However, with the advancement in dental imaging with the introduction of cone beam CT, recent studies pointed to a broad variation of the incidence, ranging from 0.09% to 36% [11,12,24]. This wide variation is mainly due to differences in the sample size and type of radiography incorporated for each study. One of the meta-analysis revealed that studies carried out using panoramic images showed a relatively lower incidence than the studies with computed tomography images [18,24,26].

Chavez-Lomeli et al. [19] gave a theory for this variation in mandibular canal anatomy. They suggested that during embryologic development of the mandible, the branches of the mandibular nerve innervating the three groups of mandibular teeth fuse together and form a single unified nerve in a single mandibular canal. Thus, lack of fusion of these nerves results in the existence of accessory canals [19]. In 1973, Kiersch and Jordan [4] suggested the cause of misinterpretation of a single canal as a bifid canal in a panoramic radiograph. They observed that the osteocondensation image produced by the insertion of the mylohyoid muscle into the internal mandibular surface mimics a bifid mandibular canal [4]. However, analysis of CBCT images would not result in such interpretation as the bifurcation can be visualized in three different spatial planes. Bifid mandibular canals have showed higher prevalence in females [10,14,15]. However, the gender differences could be more related to the

population observed rather than to the type of radiographic examination.

Presence of a bifid mandibular canal may have various important clinical implications [4,15,18,27]. Performing a third molar surgery in such cases may cause excessive bleeding or numbness, if the accessory canal is not taken into consideration [10]. Inadequate anesthesia, complications in procedures such as endodontics, dental implants and mandibular osteotomy, are the other

problems if mandibular canal variations are not recognized [22].

4. CONCLUSION

The presence of bifid mandibular canals is an unusual occurrence. Adequate knowledge of both the anatomy and the anatomical variations of the inferior alveolar canal are essential to prevent any complications during mandibular dental procedures. CBCT images prove to be the most preferable tool for investigating, identifying and confirming such variations of the canal.

REFERENCES

1. Carter RB, Keen EN (1971) The intramandibular course of the inferior alveolar nerve. *Journal of Anatomy* 108(3): 433-440.
2. Moiseiwitsch JRD (1998) Position of the mental foramen in a North American, white population. *Oral Surgery, Oral Medicine, Oral Pathology, Oral Radiology, and Endodontics* 85(4): 457-460.
3. Wadu SG, Penhall B, Townsend GC (1997) Morphological variability of the human inferior alveolar nerve. *Clinical Anatomy* 10(2): 82-87.
4. Nikzad S, Azari A, Sabouri S (2008) Double mandibular foramina and canal: Report a case with interactive CT-based planning software. *Iranian Journal of Radiology* 5(2): 83-86.
5. Worth HM (1963) Normal radiographic appearances of the teeth and jaws and variations within the normal. *Principles and Practice of Oral Radiologic Interpretation*. Chicago, IL: Year Book Medical Publishers, Inc. 15-79.
6. White SC, Pharoah MJ (2006) (Eds.) *Oral radiology, principles and interpretation*. 5th (Edn.) St. Louis, Missouri: Elsevier: 184.
7. Ghaemina H, Meijer GJ, Soehardi A, et al. (2009) Position of the impacted third molar in relation to the mandibular canal. Diagnostic accuracy of cone beam computed tomography compared with panoramic radiography. *International Journal of Oral and Maxillofacial Surgery* 38(9): 964-971.
8. Worthington P (2004) Injury to the inferior alveolar nerve during implant placement: A formula for protection of the patient and clinician. *The International Journal of Oral & Maxillofacial Implants* 19(5): 731-734.
9. Nortje CJ, Farmen AG, Grotepass FW (1977) Variations in the normal anatomy of the inferior dental (mandibular) canal: A retrospective study of panoramic radiographs from 3612 routine dental patients. *The British Journal of Oral Surgery* 15(1): 55-63.
10. Langlais RP, Broadus R, Glass BJ (1985) Bifid mandibular canals in panoramic radiographs. *The Journal of the American Dental Association* 110(6): 923-926.
11. Devito KL, Tamburús JR (2001) Anatomy of the mandibular canal: Radiological classification of its variations. *Revista da Associação Paulista de Cirurgioes Dentistas* 55(4): 261-266.
12. Rossi PM, Brúcker MR, Rockenbach MIB (2009) Bifid mandibular canals: Panoramic radiographic analysis. *Revista de Ciências Médicas* 18(2): 99-104.

13. Rouas P, Nancy J, Bar D (2007) Identification of double mandibular canals: Literature review and three case report with CT scans and cone beam CT. *Dento-maxillo-facial Radiology* 36(1): 34-38.
14. Naitoh M, Hiraiva Y, Aimiya H, et al. (2009) Observation of bifid mandibular canal using cone beam computerized tomography. *The International Journal of Oral & Maxillofacial Implants* 24(1): 155-159.
15. Kuribayashi A, Watanabe H, Imaizumi A, et al. (2010) Bifid mandibular canals: Cone beam computed tomography evaluation. *Dento-maxillo-facial Radiology* 39(4): 235-239.
16. Fu E, Peng M, Chiang CY, et al. (2014) Bifid mandibular canals and the factors associated with their presence: A medical computed tomography evaluation in a Taiwanese population. *Clinical Oral Implants Research* 25(2): e64-e67.
17. de Oliveira-Santos C, Souza PH, De Azambuja Berti-Couto SA, et al. (2012) Assessment of variations of the mandibular canal through cone beam computed tomography. *Clinical Oral Investigations* 16(2): 387-393.
18. Sanchis JM, Peñarrocha M, Soler F (2003) Bifid mandibular canal. *Journal of Oral & Maxillofacial Surgery* 61(4): 422-424.
19. Kim MS, Yoon SJ, Park HW, et al. (2011) A false presence of bifid mandibular canals in panoramic radiographs. *Dento-maxillo-facial Radiology* 40(7): 434-438.
20. Arensburg B, Nathan H (1979) Anatomical observation of the mylohyoid groove, and the course of the mylohyoid nerve and vessels. *Journal of Oral Surgery* 37(2): 93-96.
21. Xie Q, Wolf J, Soikkonen K, et al. (1996) Height of mandibular basal bone in dentate and edentulous subjects. *Acta Odontologica Scandinavica* 54(6): 379-383.
22. Auluck A, Pai KM, Shetty C (2005) Pseudo bifid mandibular canal. *Dento-maxillo-facial Radiology* 34(6): 387-388.
23. Bogdan S, Pataky L, Barabas J, et al. (2006) Atypical courses of the mandibular canal: Comparative examination of dry mandibles and x-ray. *Journal of Craniofacial Surgery* 17(3): 487-491.
24. Wadhawani P, Mathur RM, Kohli M, et al. (2008) Mandibular canal variant: A case report. *Journal of Oral Pathology & Medicine* 37(2): 122-124.
25. Fukami K, Shiozaki K, Mishima A, et al. (2012) Bifid mandibular canal: Confirmation of limited cone beam computed tomography findings by gross anatomical and histological investigations. *Dento-maxillo-facial Radiology* 41(6): 460-465.
26. Lew K, Townsend G (2008) Failure to obtain adequate anaesthesia associated with a bifid mandibular canal: A case report. *Australian Dental Journal* 51(1): 86-90.
27. Mizbah K, Gerlak N, Maal TJ, et al. (2012) The clinical relevance of bifid and trifid mandibulars canals. *Oral and Maxillofacial Surgery* 16(1): 147-151.