

# Arrhythmic Electrical Storm for Ventricular Tachycardia Finished with Propofol: Clinical Case

Carlos Hernán Ducuara Tovar\*, Lázaro Jhoni Erazo and Guarionex Estrella Gomez

*Institute of Cardiology and Cardiovascular Surgery, Havana, Cuba*

Correspondence should be addressed to Carlos Hernán Ducuara Tovar, [medicicar@hotmail.com](mailto:medicicar@hotmail.com)

**Received Date:** November 21, 2020; **Accepted Date:** December 10, 2020; **Published Date:** December 17, 2020

## ABSTRACT

Arrhythmic electrical storm (ASD) is a critical situation that puts the patient's life at risk, being frequent in the early or late carriers of the implantable cardioverter-defibrillator (CDAI), characterized by the presence of three or more episodes of Ventricular tachycardia (TV) or Ventricular fibrillation (VF) and/or malignant ventricular arrhythmias (AVM), in less than 24 hours, requiring effective and appropriate therapy by the device (Cardioversion-defibrillation-shock-EAT: Anti-tachycardia stimulation).

Its etiology is multifactorial, being the most frequent cause of multiple discharges; the increase in the frequency of TV and VF episodes without an objective precipitant, being the structural heart disease and ventricular dysfunction predictors of AVM.

TV is the most identified arrhythmia, followed by VF, which are in a destabilizing role both hemodynamic and mental.

The treatment must be in ICU, by Cardiology, monitoring, extension studies, and search for precipitating factors, interrogation of the ICD and/or reprogramming, use of antiarrhythmics, catheter ablation, generator replacement and cardiac transplantation as the last instance.

This article documents the case of a monomorphic sustained TV electrical storm in a patient with CDAI that was not terminated with conventional antiarrhythmic treatment, but with sedatives/anesthetics.

## **KEYWORDS**

Electrical storm; Ventricular tachycardia; Ventricular fibrillation; Arrhythmias; DAI implantable automatic defibrillator

## INTRODUCTION

The implantable cardioverter-defibrillator (CDAI) is a device used in both primary and secondary prevention of patients at high risk of sudden cardiac death caused by the appearance of malignant ventricular arrhythmias (AVM)

and whose benefit is reflected in the improvement of the life of those who suffer [1,2].

The CDAI is designed to identify (AVM) and finalize them by antitachycardia therapy (ATP) or electric shock. These downloads may be inappropriate when they are unnecessary or affected when they are in the presence of a

**Citation:** Carlos Hernán Ducuara Tovar, Arrhythmic Electrical Storm for Ventricular Tachycardia Finished with Propofol: Clinical Case. J Heart 2(2): 37-45.

malignant PV or TV. The entity's definition is given by the appearance of three or more episodes of TV or VF in 24 hours, separated by five minutes or more of sinus rhythm, with the requirement of electrical cardioversion or specific and successful defibrillation by the device (EAT and/or shock); the conclusion of the event is considered after one week without arrhythmias. The previous configuration of the arrhythmic thunderstorm, constituting a true vital emergency that requires an intensive, multidisciplinary integral management, with the use of combined and staggered therapy, bringing benefits but also an increased risk of complications [3-5].

The worldwide incidence of arrhythmic thunderstorm in patients with CDAI ranges between 10% and 40%, there are some populations with greater susceptibility: Men, older adults, those with secondary prevention objective and with basic pathologies such as: Ischemic heart disease (IC), Chronic renal failure (CRF), Brugada syndrome (SB), Long QT syndrome (SQTL), Hypertrophic cardiomyopathy (MCH) and Arrhythmogenic right ventricular dysplasia (DAVD) [5]. The selected downloads are presented in the order between 17% and 64%, while inappropriate downloads appear between 10% and 24%.

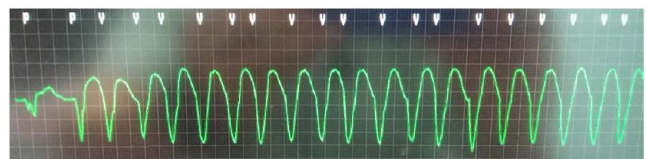In relation to the present clinical case, the presence of ventricular tachycardia is documented as the triggering event and our electrophysiological mechanisms probably involved in automation and reentry and in the pharmacological treatment established after refractoriness to conventional treatment having direct effect on modulation autonomous nervous system and decreased potential for transmembrane action on ventricular myocardial fibers [6-10].

## **2. CASE STUDY**

Male patient of 61 years of age, white race, of urban origin, Weight: 77 Kg, Size: 1.62 Mt/cm, with

pathological history: Arterial hypertension and episode of sustained ventricular tachycardia (TVS) in 2015, who came in treatment with enalapril 20 mg tablets: 1 every 12 hours, hydrochlorothiazide tablets 25 mg: 1 daily, acetylsalicylic acid tablets 125 mg: 1 daily, propranolol tablets 40 mg: ½ every 8 hours, amiodarone tablets 200 mg: 1 a day Surgical: right hand tenorrhaphy secondary to trauma with a short-sighted object in 1989, laparotomy plus appendectomy in 1992 and left inguinal herniorrhaphy in 2001. Interventions: Performing coronary angiography in 2015: Epicardial arteries without significant angiographic lesions. Implant of the CDAI in February 2015, with a pacemaker function anti bradycardia - anti tachycardia. Indication: Secondary prevention (Recommendation/Evidence IC): TVS not associated with CPR and normal LVEF. Toxic: Ex-smoker of ½ box of cigarettes per day for 10 years. Former occasional alcohol drinker for 30 years. Allergic: Denies.

The patient went to the cardiovascular emergency service of the institute of cardiology and cardiovascular surgery of Havana, Cuba in October 2018 for presenting a clinical picture of 12 hours of evolution consisting of palpitations, high intensity, sudden onset, constant, triggered at rest, associated with dizziness, anxiety, diaphoresis, deterioration of its functional class and successive discharges of the CDAI, which generated considerable chest discomfort. Therefore, admission, monitoring, extension studies, mediated support and intensive treatment, among others, are decided.



**Figure 1:** Monomorphic sustained ventricular tachycardia with left branch blocking morphology. Seen in EKG of 12 derivations.

It is documented in the electrocardiogram and monitor: Figure 1.

Vital signs: Blood pressure: 126/72 mmHg, Heart rate: 143 bpm, Respiratory rate: 20 per minute, Temperature: 36.4 Axillary degrees, Saturation: 97% ambient. Cardiovascular Apparatus: R1 with changing intensity and R2 of good tone and intensity, rhythmic, tachycardia, no murmurs. Arterial pulse: Frequency: Fast, with regular rhythm. Jugular venous pulse: Wave (a) In “cannon”. Respiratory system: Preserved vesicular murmur, no rales-no crepitus, no wheezing. Tips: No edemas. Neurological: Alert, oriented, language and cognitive functions preserved, no motor deficit, nor sensitive, Glasgow 15/15.

Diagnostic printing is performed: Monomorphic sustained ventricular tachycardia with left branch block morphology in a clinically stable patient and trigger of the current arrhythmic electrical storm in cardioverter carrier - implantable automatic defibrillator.

**Test Results**

1. Arterial gases PH: 7,496 PCO2: 32.9 mmHg PO2: 97.1% HCO3: 25 mEq/L. BE: 3.6 mmol/l: Uncompensated respiratory alkalosis. No evidence of hypoxemia. Treatment started.
2. Ionogram: Sodium: 130.6 mEq/L, Potassium: 3.73mg/dl, Chlorine: 99.9 mEq/L, Calcium: 9.4 mg/dl: No electrolyte disorder except for a Light Hyponatremia. Treatment started.
3. Serum Markers: Troponin (I): Normal, CKMB: Normal. Presence of acute myocardial infarction (AMI) is ruled out, because there is no evidence of myocardial damage (There is no elevation of cardiac troponins to values higher than the 99<sup>th</sup> percentile of the LSR), nor presence of necrosis in a clinical context compatible with myocardial ischemia.

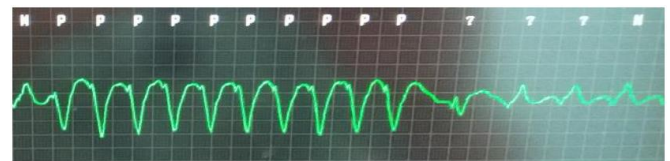
4. Glycemia: 6.1 mmol/L: No disorder in carbohydrate metabolism.
5. Blood count: Leukocytes:  $7.6 \times 10(3)/L$  Hb.14.8 gr/dl Hto. 42% Plt.  $227 \times 10(3)/L$ : The three cell lines are preserved. There are no infections, no signs of myocarditis.
6. Creatinine: 117 umol-TFG: 63.8 mL/min. IRC base stage II.
7. Transaminases: Alt 11 IU/L Ast 10 IU/L: No liver dysfunction.
8. Transtoracic echocardiogram: LVEF: 65%, TAPSE 23 mm; among other parameters.

**Conclusion**

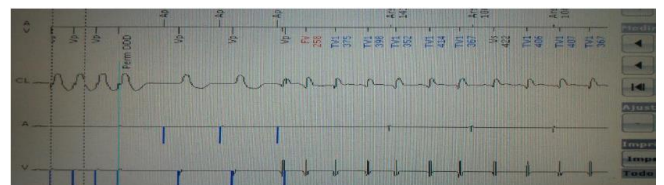
Preserved biventricular systolic function, no signs of resting ischemia, competent valve apparatus, and low probability of PHT [7].

Endovenous anti-arrhythmic pharmacological therapy was initiated according to recommendations and levels of international evidence without improvement.

Additionally it was evidenced that antitachycardia therapy (ATP) through the CDAI; reverses monomorphic TV at the patient's base rhythm, however it is transiently solving ventricular arrhythmia (Figure 2 and Figure 3).

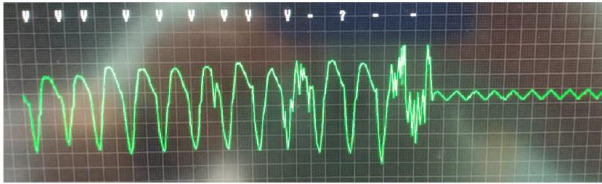


**Figure 2:** Monitor: Burst and ramp-type ATP during TV. Ventricular arrhythmia temporarily resolves.



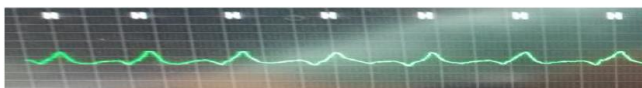
**Figure 3:** Device is interrogated: Programmer connected to the CDAI, more than 120 ATP are documented. Note: AV dissociation and TV recurrence after effective ATP.

Subsequently, treatment is staggered by modifying the interface of anti-tachycardia therapy to shocks. More than 7 electrical discharges are documented, with adequate energy (J), duration (S) and impedance ( $\Omega$ ), evidencing partial suppression of ventricular tachycardia, which passes at the patient's base rhythm and again emerges with a rhythm of electrostimulation of the antitachycardia function of the CDAI (Figure 4) [8-12].



**Figure 4:** Monitor: CDAI detects the TV for eight beats that meet the frequency criteria; 2.5 seconds later, once loaded and synchronized: Download the Shock. Temporary TV reverts.

Finally, together with the cardiovascular anesthesiology service, it was decided to administer sedative agents - endovenous anesthetics; among them Propofol (bolus injection) and Midazolam (continuous infusion) respectively; protecting airway and other vital signs [13]. After the administration of this pharmacological cocktail the TVSMBRI (Monomorphic Sustained Ventricular Tachycardia with Left Branch Blocking Morphology) immediately resolves, terminating the emergency that threatened the patient's life and generated appropriate, successive and effective discharges by the device. Thus ends the episode of arrhythmic electric storm that could have led not only to major cardiovascular complications among them: More myocardial injury, persistence of mechanical stress from discharges, drop in cardiac output, cardiogenic shock, without ruling out that arrhythmia perse, which resolved temporarily with the ATP and Crash of the CDAI, the dreaded event of sudden cardiac death will be presented (Figure 5) [15].



**Figure 5:** Final resolution of the TV-TE and the transition to the patient's EKG base pattern permanently.

## DISCUSSION

Therefore, it is considered that according to the patient's background plus the electrocardiographic findings evidenced in the monitor and programmer, as well as what was documented in the physical examination, what was revealed in the examinations that allowed to correct the basic and electrolytic acid disorders, also discarding triggering events such as acute myocardial infarction or myocarditis, as well as the appearance of arrhythmia despite being in oral antiarrhythmic treatment and its persistence without being able to resolve it with emergency intravenous infusion, or with anti-tachycardia therapies, or with one's own downloads (clarifying that they temporarily resolved the TV and protected it against sudden death), not even with the staggering to the modifications of the ATP interface - shocks made in the programmer, managed to finish the arrhythmia. It was really the use of sedative anesthetic drugs such as propofol and midazolam (Drugs that were used for sedation before a patient with physical and mental stress on the verge of hemodynamic collapse and not as cataloged therapy with anti-arrhythmic properties for TV termination) that acted immediately and definitively in the resolution of monomorphic sustained ventricular tachycardia with left bundle branch block morphology; thanks to the intervention on the reduction of the potential for transmembrane action of myocyte and the effects on the electrophysiological mechanisms of reentrada and automatismo involved in TV and additionally mediated by the autonomic nervous system [16-21].

Propofol is a phenolic derivative with widely used sedative and hypnotic properties. Among its cardiovascular effects are: Dose-dependent reduction of preload, afterload and myocardial contractility are the most recognized [22]. Although, others have recently emerged as its potential protective role in ischemia-reperfusion damage, its influence on the cardiac conduction system and the ability to modify the phases of

the action potential by acting on the ionic membrane channels of the myocyte. These effects give the drug antiarrhythmic properties, although the evidence and clinical experience in this field are still scarce. Propofol has been shown to have beneficial effects by decreasing the tendency to shorten the action potential. Reduction of incidence of tachyarrhythmias. The intrinsic antiarrhythmic effects of propofol appear to be mediated by their demonstrated inhibitory effects on the potassium channels responsible for phase 1 and 3 repolarization (Ito yIKUR and ATP-sensitive, respectively) and the calcium channels involved in phase 2 (ICa). To the aforementioned direct effects of propofol on the myocardium and conduction tissue is added its influence on the autonomic nervous system, which indirectly affects the heart. Propofol suppresses all the activity of the autonomous system, although the effect is significantly greater on the adrenergic system [23-27].

Additionally, it is considered that midazolam possibly contributed to acting on the autonomic nervous system in the mechanisms of the TV, because when disconnecting the patient's state of consciousness during the anesthesia sedation process there has been a notable decrease in the degree of sympathetic excitation in the fibers of the ventricular heart muscle, directly affecting the arrhythmia substrate and/or reentry and automatism mechanisms.

It is important to state that TV encompasses all rapid rhythms (three or more complex) originating below the bifurcation of the common trunk of the bundle, with the exception of ventricular flutter and fibrillation [28].

Its classification is: Sustained TV (as was the case of our patient) and is sustained if it is necessary to interrupt it by means of pharmacological, mechanical or electrical procedures, because it is suffering from severe hemodynamic deterioration or has a prolonged duration. In electrophysiology laboratories, TV is usually

considered sustained for more than 30 seconds. The following are unsupported TV, monomorphic TV and polymorphic TV.

The main etiologic agents are ischemic heart disease, dilated cardiomyopathy, hypertrophic heart disease, valvular heart disease, hypertensive heart disease, drug arrhythmogenesis, congenital and acquired long QT syndrome, infections that occur with myocarditis, hypoxia, electrolyte, metabolic disorders, physical stress or psychic with or without associated and idiopathic heart disease in structurally normal hearts [29].

The TV suggests a reentry mechanism (micro and macro reentry), ectopic focus, automatism (abnormal, induced and triggered). Microrreentry consisting of a reentry phenomenon in a small area of ventricular myocardium. Explain the typical TVs that occur chronically and recurrently (wide and monomorphic QRS) frequently between 130 bpm to 200 bpm. Those of macro reentry encompasses a wide aneurysmal or necrotic area (polymorphic QRS and irregular ventricular frequency). In automatism there is a spontaneous depolarization of ventricular myocardial fibers. It probably explains non-fast TVs. In the triggered automatism there is an electrical stimulation in previously passive fibers. Less commonly, focal TV can be caused by adrenergic stimulation. The automaticity for damage of Purkinje fibers has been proposed as some sensitive catecholamine mechanisms [30].

For the diagnosis of TV, Brugada electrocardiographic criteria are used among others: 1) Absence of RS, rS, Rs or rs complexes in precordial. 2) Interval from the beginning of the R to the end of the S > 100 ms. 3) Dissociation AV. 4) Morphological criteria in favor of TV in V1 and V6 simultaneously. V1: BRD - Mono or biphasic pattern. BRI - Bimodal QS or rS pattern with r > 30 ms, S notch, and rS > 60 ms. V6: BRD - rS or QS

pattern. BRI - Pattern qR, QS. In the present clinical case we arrive at the diagnosis of TV using steps 1 and 2 in electrocardiographic strip with the precordial leads.

The treatment of sustained VT always represents an emergency situation, on the one hand the importance of hemodynamic alterations and on the other the danger that becomes a ventricular fibrillation. Interrogation and physical examination is important. 12 lead electrocardiogram. Complementary. Specific treatment. Bed the patient. Monitoring Channel vein Oxygen (if necessary). Correct electrolyte and acid-basic disorders. Intensive surveillance. According to previous literature: If there is hemodynamic instability: Synchronized Electrical Cardioversion. Anti-arrhythmic infusions for stable wide QRS tachycardia: Procainamide, dose IV, 20 mg/min - 50 mg/min until arrhythmia suppression, hypotension, QRS widening >50% or until the maximum dose of 17 mg/kg is reached. Maintenance infusion: 1 mg/min - 4 mg/min. Avoid in case of prolonged QT or ICC. Amiodarone, dose IV: First dose: 150 mg for 10 minutes. Repeat if necessary. If the TV reappears. Follow with maintenance infusion of 1 mg/minute for the first 6 hours. Sotalol, dose IV: 100 mg (1.5 mg/kg) IV for 5 minutes. Avoid if there is prolonged QT. According to recent literature: Hemodynamically unstable continues to confirm electrical cardioversion. Hemodynamically stable: Consider: If you are suffering from structural heart disease: Cardioversion (Class I), Procainamide IV (Class IIa), amiodarone or sotalol IV (Class IIb), if there is no termination (Sedation as support and not as anti-arrhythmic treatment, reevaluation of anti-arrhythmic therapy options) or be prepared in final instances with catheter ablation (Class I). If there is no structural heart disease and electrocardiogram with idiopathic ventricular arrhythmia morphology: Verapamil or Beta blockers (Class IIa).

The thunderstorm is a frequent and critical event in patients with implantable cardioversion-defibrillator, early or late in relation to the implant. Sometimes it is presented as debut and tends to recurrences. Its causes are varied and hardly identifiable. It includes several clinical syndromes, the most frequent arrhythmia is ventricular tachycardia. It is destabilizing, hemodynamic and psychic. The hospital stay is very high. The device protects against episodes of sudden death. Therapy with antitachycardia stimulation is well tolerated, not so the shocks that cause significant discomfort. Structural heart disease and depressed ventricular function are a predictive factor of malignant ventricular arrhythmias. The therapeutic confrontation of the thunderstorm is diverse but mixed therapy is usually required, device plus antiarrhythmic drugs, which entails benefits and risks.

Multiple discharges, whether appropriate or not, cause catecholamine release due to acute stress, which facilitates the appearance of new arrhythmias and imbalance of the sympathetic/parasympathetic tones. In some patients this leads to anxiety, posttraumatic stress and depression. Any bad psychological adaptation should be detected immediately for the fastest possible therapeutic intervention.

The treatment of ASD should be focused on providing priority in emergency care. General measures of advanced cardiac life support, as appropriate. Immediate ECG monitoring (ideally with registration and printing of events). Install venous pathways. Laboratory analysis: Na, K, Mg, Ca, NUS, Cr, Troponins, CK-MB and others according to clinical suspicion. 12 lead electrocardiogram. Review outpatient drug treatment: diuretics, antiarrhythmics, abandonment therapy. Question about drug and alcohol use [31].

Correct precipitating causes: Ischemia, electrolyte abnormalities. Magnet in case of inappropriate discharges

and incessant ventricular arrhythmias. Pharmacological treatment: Amiodarone, Lidocaine, Isoproterenol, as appropriate. Sedation using benzodiazepines, propofol. (Airway protection if necessary). Entrance in critical patients unit or coronary unit, monitored transfer. Inter-consultations to the specialist: Cardiology or ideally to the electrophysiologist. Questioning the device.

Catheter ablation is considered a type I-B recommendation for the treatment of arrhythmic storm and patients with ICD with repeated crashes. The indication after the first episode of ventricular tachycardia (TV) for patients with ischemic heart disease is considered indication IIa-B. However, TV ablation is difficult, with results highly dependent on the equipment (experience and volume of patients), and therefore, early

transfer to a specialized center is recommended in case of arrhythmic storm [32].

Finally, it is considered that more studies and clinical trials should be carried out to broaden and fully understand the different electrophysiological mechanisms and the anti-arrhythmic properties of phenolic derivatives in co-adjuvance with benzodiazepines, which are being used today for sedation - anesthesia and that could be used in the very near future not only to treat some types of ventricular tachycardia described above but also could be the starting point to provide treatments to other arrhythmias that threaten the patient's life and that may be available and cataloged in a near future as new antiarrhythmic drugs.

## REFERENCES

1. Tornés Bázquez FJ, Cisneros Clavijo P, Dorantes Sánchez M, et al. (2008) Arrhythmic electrical storm in patients with implantable cardioverter-defibrillator. *Archives of Cardiology of Mexico* 78 (1): 68-78.
2. Montero-Tinnirello J, Magaldi M, Fontanals J, et al. (2017) Reversal of supraventricular tachyarrhythmias after propofol administration. Number of cases. *Medicina Intensiva* 41(8): 499-501.
3. Iturralde P (1997) *Arritmias cardíacas*. DF: McGraw-Hill Interamericana, Mexico: 145-183.
4. Cronin EM, Bogun FM, Maury P, et al. (2019) 2019 HRS/EHRA/APHRS/LAHRS expert consensus statement on catheter ablation of ventricular arrhythmias. *EP Europace* 21(8): 1143-1144.
5. Callaway C (2011) *SopORTE vital cardiovascular avanzado*. American Heart Association.
6. Al-Khatib SM, Stevenson WG, Ackerman MJ, et al. (2018) 2017 AHA/ACC/HRS guideline for management of patients with ventricular arrhythmias and the prevention of sudden cardiac death: A report of the American college of cardiology/American heart association task force on clinical practice guidelines and the heart rhythm society. *Journal of the American College of Cardiology* 72(14): e91-e220.
7. Madariaga Romo R (2012) Emergencies in patients with implantable cardioverter-defibrillator. Frequent shock from the defibrillator. Basic concepts and management. *Medical Journal of Chile* 27 (3): 177-183.
8. Fernández-Lozano I (2016) Comments on the ESC 2015 guideline on the treatment of patients with ventricular arrhythmias and prevention of sudden cardiac death. *Spanish Journal of Cardiology* 69(2): 94-101.
9. Myerburg RJ, Quinones MA, Roden DM, et al. (2006) ACC/AHA/ESC 2006 guidelines for management of patients with ventricular arrhythmias and the prevention of sudden cardiac death. *Europace* 8: 746-837.
10. Poole JE, Johnson GW, Hellkamp AS, et al. (2008) Prognostic importance of defibrillator shocks in patients with heart failure. *New England Journal of Medicine* 359(10): 1009-1017.
11. Sears SF, Conti JB (2002) Quality of life and psychological functioning of ICD patients. *Heart* 87(5): 488-493.



12. Israel CW, Serge Barold S (2007) Electrical storm in patients with an implanted defibrillator: A matter of definition. *Annals of Noninvasive Electrocardiology* 12(4): 375-382.
13. Gatzoulis KA, Andrikopoulos GK, Apostolopoulos T, et al. (2005) Electrical storm is an independent predictor of adverse long-term outcome in the era of implantable defibrillator therapy. *EP Europace* 7(2): 184-192.
14. Bunch TJ, White RD, Friedman PA, et al. (2004) Trends in treated ventricular fibrillation out-of-hospital cardiac arrest: A 17-year population-based study. *Heart Rhythm* 1(3): 255-259.
15. Pinski SL (2000) Emergencies related to implantable cardioverter-defibrillators. *Critical Care Medicine* 28(10): N174-N180.
16. Pinski SL, Fahy GJ (1995) Current perspectives. The proarrhythmic potential of implantable cardioverterdefibrillators. *Circulation* 92: 1651-1664.
17. Healy E, Goyal S, Browning C, et al. (2004) Inappropriate ICD therapy due to proarrhythmic ICD shocks and hyperpolarization. *Pacing and Clinical Electrophysiology* 27(3): 415-416.
18. Perkiomaki JS, Couderc JP, Daubert JP, et al. (2003) Temporal complexity of repolarization and mortality in patients with implantable cardioverter defibrillators. *Pacing and Clinical Electrophysiology* 26(10): 1931-1936.
19. Krivan L, Kozák M, Sepsi M, et al. (2004) Specific complications in the treatment with implantable cardioverter-defibrillators. *Casopis Lekarů Ceskych* 143(8): 521-525.
20. Verma A, Kilicaslan F, Marrouche NF, et al. (2004) Prevalence, predictors, and mortality significance of the causative arrhythmia in patients with electrical storm. *Journal of Cardiovascular Electrophysiology* 15(11): 1265-1270.
21. Clements PAD (2003) Hazards of performing chest compressions in collapsed patients with internal cardioverter defibrillators. *Emergency Medicine Journal* 20(4): 379-380.
22. Mahajan A, Moore J, Cesario DA, et al. (2005) Use of thoracic epidural anesthesia for management of electrical storm: A case report. *Heart Rhythm* 2(12): 1359-1362.
23. Dandamudi G, Ghumman WS, Das MK, et al. (2007) Endocardial catheter ablation of ventricular tachycardia in patients with ventricular assist devices. *Heart Rhythm* 4(9): 1165-1169.
24. Wilkoff BL, Auricchio A, Brugada J, et al. (2008) HRS/EHRA expert consensus on the monitoring of cardiovascular implantable electronic devices (CIEDs). *Europace* 10(6): 707-725.
25. Dorian P (1997) Etiologies of electric storm. *Heart and Vessel Diseases Archives - Practice* 90: 27-31.
26. Burjorjee JE, Milne B (2002) Propofol for electrical storm; a case report of cardioversion and suppression of ventricular tachycardia by propofol. *Canadian Journal of Anesthesia* 49(9): 973-977.
27. Suzuki H, Torigoe K, Numata O, et al. (2000) Infant case with a malignant form of Brugada syndrome. *Journal of Cardiovascular Electrophysiology* 11(11): 1277-1280.
28. Srivatsa UN, Ebrahimi R, El-Bialy A, et al. (2003) Electrical storm: Case series and review of management. *Journal of Cardiovascular Pharmacology and Therapeutics* 8(3): 237-246.
29. Calkins H (2000) Summary and comment. Sympathetic blockade for patients experiencing "electrical storm". *Cardiology* 1109: 1.
30. Nademanee K, Taylor R, Bailey WE, et al. (2000) Treating electrical storm: Sympathetic blockade versus advanced cardiac life support-guided therapy. *Circulation* 102(7): 742-747.



31. Manolis AG, Katsivas AG, Vassilopoulos C, et al. (2002) Electrical storms in an ICD-recipient with 429 delivered appropriate shocks: therapeutic management with antiarrhythmic drug combination. *Journal of Interventional Cardiac Electrophysiology* 6(1): 91-94.
32. Bänsch D, Oyang F, Antz M, et al. (2003) Successful catheter ablation of electrical storm after myocardial infarction. *Circulation* 108(24): 3011-3016.